

Case Report

Mayer-Rokitansky-Kuster-Hauser (MRKH) syndrome: A Case Report

Jadhav Mayuri*, Nikam Vasudha**, Ghorpade Vijay***, Patil Asha****, Pote A J*****.

*Resident, **Prof and Head, ****Professor, *****Lecturer, Department of Anatomy, Dr. D.Y.Patil Medical College, Kolhapur, Maharashtra, India

***Assistant Professor, Department of Obstetrics and Gynaecology, Terna Medical College, Navi Mumbai, Maharashtra, India

DOI : 10.5455/jrmds.20142120

ABSTRACT

The Mayer-Rokitansky-Küster-Hauser (MRKH) syndrome is a congenital disorder characterized by aplasia of the uterus and the upper part of vagina in an XX individual with normal development of secondary sexual characteristics. To help establish the best criteria for early diagnosis and treatment options for a comprehensive therapeutic approach to MRKH patients, we report the case of a 19-year-old woman who presented with primary amenorrhea. Correct evaluation of these patients and proper management is mandatory.

Key words: Primary amenorrhea, mullerian duct anomalies, MRKH syndrome

INTRODUCTION

Mayer-Rokitansky-Kuster-Hauser syndrome is an uncommon condition, with an incidence of 1 in 4000-5000 female births [1,2], and is the second most frequent cause of primary amenorrhea after gonadal dysgenesis [3]. The reproductive abnormalities of MRKH syndrome are due to incomplete development of the Müllerian duct. This structure in the embryo develops into the uterus, fallopian tubes, cervix, and the upper part of the vagina. The cause of the abnormal development of the Müllerian duct in affected individuals is unknown. This mullerian duct abnormality is characterized by congenital aplasia of the uterus and the upper part (2/3) of vagina, in young women presenting otherwise with normal endocrine status. It may include absence or hypoplasia of the uterus and fallopian tubes. The patients present with normal secondary sexual characteristics, as the functional ovaries are present, but menstruation is absent [4].

Syndrome is classified into three types according to the involvement of other systems than reproductive system. The typical syndrome (type I) is represented by abnormalities restricted to the reproductive system. The second one (type II) is an atypical syndrome, with the presence of asymmetric uterine remnants and abnormal uterine tubes. Such syndrome type may be associated with ovarian disease, congenital renal, bone abnormalities and hearing defects. A third one, the so called MURCS type, involves utero-vaginal

hypoplasia or aplasia, renal, bone and cardiac malformations [1-3].

Renal malformations include: unilateral agenesis, horse-shoe kidney, renal hypoplasia, ectopic kidneys and hydronephrosis. Bone malformations occur particularly in the vertebrae, most commonly with vertebral fusion (particularly cervical vertebrae), Klippel-Feil syndrome and scoliosis. Cardiac alterations and digital alterations such as syndactyly and polydactyly are rarer than those previously mentioned [1].

The cause of syndrome remains unknown, but the increased number of cases in familial aggregates raises the hypothesis of a genetic cause [1].

CASE REPORT

We report the case of a 19-year-old woman who presented with no onset of menstrual cycle (primary amenorrhea). Her height was 168 cm, weight 54 Kg, and blood pressure 120/70 mm Hg. No other affected members in the family were detected. At clinical examination, the patient demonstrated a development of secondary sexual characteristics compatible with her chronological age. Hormonal studies were in normal limit. At gynaecological examination a grooved urethra with elevated edges was observed. Speculum examination was not performed.

Trans-abdominal ultrasonography did not demonstrate the presence of uterus. There was difficulty in visualizing the ovaries. Therefore, a pelvic MRI examination was conducted. At magnetic resonance imaging, the uterus could not be visualized and the ovaries presented with good volume and without any abnormality. Also, the vaginal canal could not be visualized.

Fig 1 : USG shows absent uterus

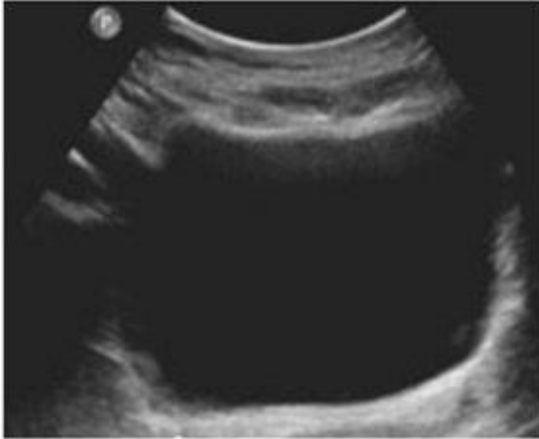
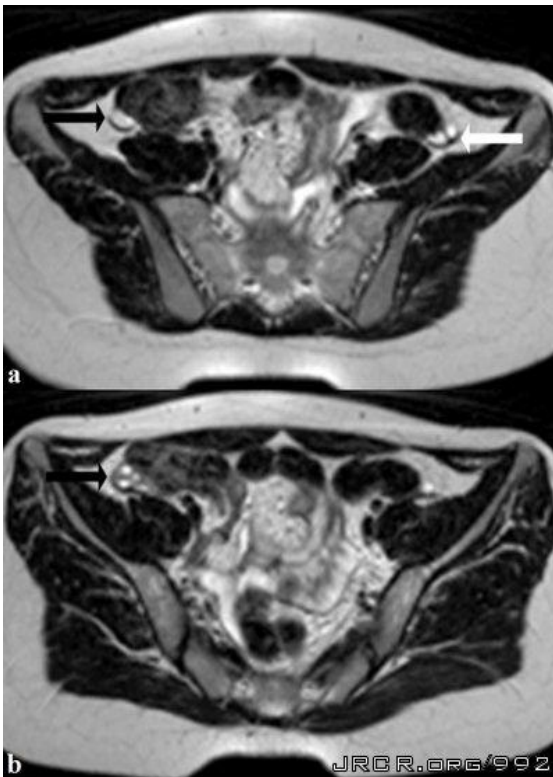


Fig 2: MRI shows absent uterus and presence of ovaries



Genetic evaluation revealed karyotype 46 XX, thus determining the diagnosis of MRKH syndrome. A surgeon specialized in reconstructive surgery and a consultant psychologist was involved and no surgery was planned for the patient at this stage. The findings and implications regarding potential fertility and child bearing were explained to the patient. An interdisciplinary management in a specialized centre was planned.

After initial non-operative treatment, the patient underwent vaginoplasty.

DISCUSSION

The typical clinical presentation of this syndrome is primary amenorrhea, in association with or without cyclic colicky pain, in an adolescent with secondary sexual characteristics compatible with age, with no sign of virilisation. Gynaecologic examination may detect either absence of the vaginal canal or vaginal shortening [1,2,5-8].

Imaging studies such as ultrasonography and magnetic resonance imaging, in association with or without laparoscopy, are necessary to allow the determination of the anatomic characteristics of the syndrome. Ultrasonography is the initial method of choice. This method can demonstrate the absence of the uterus between the bladder and the rectum [1,5,9]. Magnetic resonance imaging is the most sensitive and specific imaging method in the evaluation of this syndrome, not only for allowing the acquisition of multiplanar images, but also for allowing the acquisition of sequences with fat saturation. It allows a good definition of anatomical alterations such as uterine agenesis, as well as evaluating ovaries, vagina and associated anomalies [1,4,5,9].

Laparoscopy is indicated only in cases where the evaluation by the two previous imaging methods is inconclusive and provided this method allows the definition of a therapeutic strategy. Once the diagnosis of Mayer-Rokitansky-Kuster-Hauser syndrome is established, a clinical investigation should be undertaken to identify possible associated malformations [1,4].

The final diagnosis is achieved by the association of the imaging findings with the presence of the karyotype 46, XX. The differential diagnosis should be made with other situations where the patient presents primary amenorrhea and normal secondary sexual characteristics, such as congenital absence of uterus and vagina, isolated vaginal atresia with androgen

insensitivity syndrome and transverse vaginal septum with imperforate hymen [1].

Because of the typical anatomic alterations, MRKS syndrome generates anxiety and psychological distress with consequences on the patient's quality of life, thus requiring a multidisciplinary approach [5,6]. The indicated anatomic treatment is the surgical or non-surgical creation of a neovagina, which may allow these patients to have a normal sex life [1-6]. As the surgical approach is chosen, uterine remnants can be removed to avoid future endometriosis [1].

Patients who want to have children should be encouraged to adopt, or the possibility of having biological children by means of assisted reproduction techniques should be suggested, considering that the presence of functional ovaries in these women allow the production of normal ovules [10].

Even with advanced management of this syndrome, its diagnosis causes significant psychological distress, affecting the patients' quality of life because of the absence of menstruation and impossibility of pregnancy. The distress caused by the diagnosis may be alleviated by surgical or non-surgical treatments, by the passage of time, by counselling, by family's support and by support groups [10].

CONCLUSION

MRKH syndrome is one of the most common causes of primary amenorrhea and Ultrasonography is useful for diagnosing any associated renal anomalies. MRI is more precise than USG and less invasive and expensive than laparoscopy, contributing significantly to treatment planning and patient management. Although this condition has psychologically devastating consequences today anatomical defects can be surgically treated allowing a normal sexual function and reproduction thanks to the assisted techniques. so correct evaluation of these patients and proper management is mandatory.

REFERENCES

1. Morcel K, Camborieux L, Müllériennes A and Guerrier D. Mayer Rokitansky-Kuster-Hauser (MRKH) syndrome; Orphanet J Rare Dis. 2007;2:13
2. Sultan C, Biason-Lauber A, Philibert P. Mayer-Rokitansky-Kuster-Hauser syndrome; recent

clinical and genetic findings. Gynecol Endocrinol. 2009;25:8-11

3. Fedele L, Bianchi S, Tozzi L, Borruoto F, Vignali M . A new laparoscopic procedure for creation of a neo-vagina in Mayer-Rokitansky-Kuster-Hauser syndrome; Fertil Steril. 1996;66:854
4. Sen KK, Kapoor A. Mayer-Rokitansky-Kuster-Hauser syndrome; Ind J Radiol Imag. 2006;16: 805-7
5. Junqueira BLP, Allen LM, Spitzer RF, Lucco KL, Babyn PS, Doria AS. Müllerian duct anomalies and mimics in children and adolescents: correlative intraoperative assessment with clinical imaging. Radiographics. 2009;29:1085-103
6. Muelle GC, Hussain HK, Smith YR, Quint EH, Carlos RC, Johnson TD, DeLancey JO. Müllerian duct anomalies: comparison of MRI diagnosis and clinical diagnosis; AJR Am J Roentgenol. 2007;189:1294-302
7. Troiano RN, McCarthy SM. Müllerian duct anomalies: imaging and clinical issues. Radiology. 2004;233:19-34
8. Stainkeler FA, Woodfield CA, Hillstrom MM. Female infertility: a systematic approach to radiologic imaging and diagnosis. Radiographics. 2009;29:1353-70
9. Strübbe EH, Willemsen WNP, Lemmens JAM, Thijn CJ, Rolland R. Mayer-Rokitansky-Kuster-Hauser syndrome: distinction between two forms based on excretory urographic, sonographic, and laparoscopic findings. AJR Am J Roentgenol. 1993;160:331-4
10. Bean EJ, Mazur T, Robinson AD. Mayer-Rokitansky-Kuster-Hauser: sexuality, psychological effects, and quality of life. J Pediatr Adolesc Gynecol. 2009;22:339-46

Corresponding Author:

Dr. Jadhav Mayuri B.
202, Shantikunj, plot no 154,
Sector 21, Nerul (E),
Navi Mumbai. 400706
Email: mayoojadhav@yahoo.co.in

Date of Submission: 28/09/2013
Date of Acceptance: 18/11/2013

How to cite this article: Jadhav M, Nikam V, Ghorpade V, Patil A, Pote AJ. Mayer-Rokitansky-Kuster-Hauser (MRKH) syndrome: A Case Report. J Res Med Den Sci 2014;2(1):106-8

Source of Support: None
Conflict of Interest: None declared