

## Most Common Shades Used During Indirect Veneering Restoration-A Descriptive Study

Sweta A, Vigneshwar\*

Department of Conservative Dentistry and Endodontics, Saveetha Dental College & Hospital, Saveetha Institute of Medical and Technical Sciences, Saveetha University, Chennai, India

### ABSTRACT

**Introduction:** The direct-indirect composite veneer technique was introduced in the 1990s as a means to heat-temper composites in partial and full veneers. 1-4 in the direct-indirect technique, using similar shade selection and layering techniques that are used for the direct technique; the clinician applies a light-cured composite material to the tooth, with or without tooth preparation, without any adhesion. The composite is then shaped to a primary anatomic form with slight excess, and then light-cured. After that, the partially polymerized restoration is carefully removed (lifted) from the non-retentive, non-bonded tooth surface, heat-tempered extra-orally chairside, and finished and polished to final macro and micro anatomy. After shade try-in and confirmation of the overall fit and esthetics, the veneer is bonded to the preparation using a resin-based luting agent. Indirect laminate veneer restorations provide a valid conservative alternative to complete teeth coverage (full crown) as they avoid aggressive dental preparation; thus, maintaining tooth structure.

**Materials and methods:** This is a retrospective study in which the case records of 380 patients were reviewed and details such as gender, age, type of materials used were collected. Details were tabulated in excel and results were obtained using SPSS. Chi square analysis was performed to find out the association between different variables.

**Results:** Age range 16-25 years who received indirect veneering were at a higher rate (74.41%), age group 26-45 years (22.16%) and 46-70 years (22.06%). Male population undergoes indirect veneering than the female population which is about 62.80%, 11 teeth number is the most common tooth undergone for indirect veneering which is about 27.97%.

**Conclusion:** Within the limits of the present study, it can be concluded that A2 shade was the most common material used during indirect veneering with male predilection.

**Key words:** Indirect veneering, Shade, Male, Aesthetic, Ceramic

**HOW TO CITE THIS ARTICLE:** Sweta A, Vigneshwar, Most Common Shades Used During Indirect Veneering Restoration-A Descriptive Study, J Res Med Dent Sci, 2022, 10 (7):186-192.

**Corresponding author:** Vigneshwar

**e-mail** ✉: vigneshwart.sdc@saveetha.com

**Received:** 08-June-2022, Manuscript No. JRMDS-22-69300

Editor assigned: 10-June-2022, **PreQC No.** JRMDS-22-69300 (PQ);

**Reviewed:** 24-June-2022, QC No. JRMDS-22-69300;

**Revised:** 29-June-2022, Manuscript No. JRMDS-22-69300 (R);

**Published:** 06-July-2022

### INTRODUCTION

The word esthetic implies beauty, naturalness, and youthful appearance relative to one's age. Esthetic dentistry created new dimensions in providing esthetics and functional rehabilitation [1]. Because of esthetic demands as well as patients' awareness have been increased over the period of years, it becomes imperative for clinicians to evolve better treatment modalities to deliver higher standards of therapies using

new generation materials along with improved clinical procedure [2]. The direct-indirect composite veneer technique was introduced in the 1990s as a means to heat-temper composites in partial and full veneers [3]. In the direct-indirect technique, using similar shade selection and layering techniques that are used for the direct technique, the clinician applies a light-cured composite material to the tooth, with or without tooth preparation, without any adhesion [4-6]. The composite is then shaped to a primary anatomic form with slight excess, and then light-cured. After that, the partially polymerized restoration is carefully removed (lifted) from the non-retentive, non-bonded tooth surface, heat-tempered extra-orally chairside, and finished and polished to final macro and micro anatomy [5,7].

After shade try-in and confirmation of the overall fit and esthetics, the veneer is bonded to the preparation using a resin-based luting agent. Indirect laminate

veneer restorations provide a valid conservative alternative to complete teeth coverage (full crown) as they avoid aggressive dental preparation; thus, maintaining tooth structure [8]. The increased practice of veneering technique with indirect composites is due to improvement in the properties of composite materials in the last years. This case report describes using indirect composite laminate veneer technique for a patient with esthetic problems related to generalized diastema in the upper anterior teeth [9]. Starting with esthetic gingivectomy and ending up with laminate veneers being bonded on the teeth, a complete satisfying result was achieved. However, with no follow-up documentation yet. Indirect composite laminate veneer restorations due to polymerization outside of the oral cavity, and thus being less affected by the fluids of the oral cavity with reduced effect of polymerization shrinkage and improved mechanical properties, are superior to direct composite veneers, and could give satisfying esthetic results [10-12].

Maintaining good oral hygiene should always be advised to patients with such laminate veneers in order to keep prolonged esthetic results. The regular method used for esthetic restorations is to remove a certain amount of tooth tissue and replace the space with ceramic restorations [13]. Porcelain esthetic restorations include porcelain veneers, porcelain crowns, porcelain inlays, etc. Ceramic veneers have superior properties in both esthetic and tooth preservations and are considered as minimally invasive treatment for indirect esthetic restoration [14]. The development of dental ceramic techniques offered a veneer thickness of about 0.3–0.5 mm, decreasing tooth reduction amount and ensuring it to be within the enamel structure and effective bonding [12]. Without the exposure of dentin, sensitivity discomfort would be alleviated and enamel bonding interface also demonstrated to have higher strength. Nevertheless, studies have shown excessive

invasion for some of the veneer tooth preparations [15]. Practically, dentin exposure occurs when the prepared finishing planes exceed the enamel–dentin junction during clinical operations [16]. Poor long-term effects from non-minimally invasive operations occur due to decreased bonding strength, increased dentin sensitivity, and microleakage. Our team has extensive knowledge and research experience that has translated into high quality publications [17-36]. The aim of the study was to find the most common shades used during indirect veneering restoration.

**MATERIALS AND METHODS**

**Study setting**

A retrospective study was carried out among patients in a University hospital setting. This is based on a university setting because data available was in the similar ethnicity with the particular geographic location. The trends in the other locations that were not assessed in the study setting. Ethical approval was taken from the universal ethical committee. In total, three reviewers were involved to cross verify data.

**Sampling**

The sample was collected from records with patients' data like: PID, Name, Age, Gender, treatment, Teeth number, and Shade used in treatment, Date of their first visit from June 2019 to June 2021. 2021 and tabulation was done in a chronological order using Excel. Case sheet review was done under the examiner followed by cross verification.

The study sample size included patients who underwent perforation repair and data retrieved was n=380. Statistical method used in this study was the Chi-Square test and the software was SPSS by IBM. Patients who underwent indirect veneering were considered as dependent variables and their Age, Teeth number,

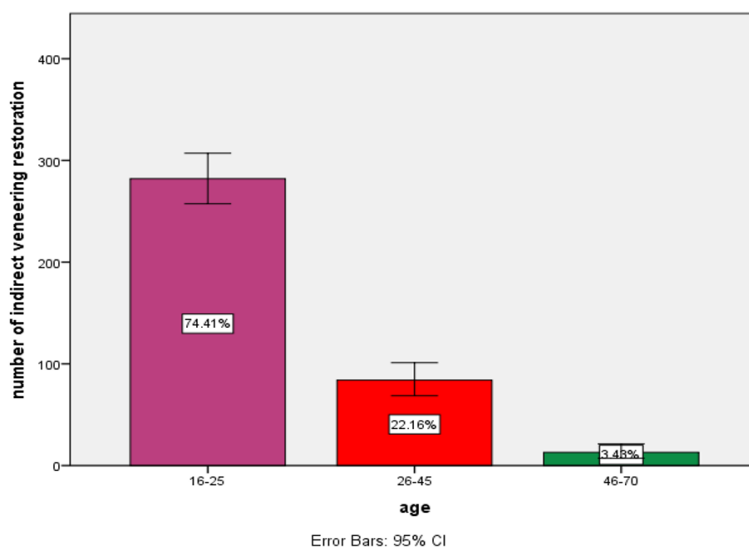


Figure 1: The bar graph of distribution of age among people who underwent indirect veneering. The age group of patients were mentioned in X-axis which were categorized as 16-25 years, 26-45 years, 46-70 years and the percentage of patients who underwent indirect veneering were mentioned in Y-axis. Of these, people of the age range 16-25 years who received indirect veneering were at a higher rate (74.41%), age group 26-45 years (22.16%) and 46-70 years (22.06%).

Gender, shade used was considered as a definite variable. The type of analysis used was Correlation and association which is a descriptive type of data analysis.

**RESULTS**

From the above study it is observed that age range 16-

25 years years who received indirect veneering were at a higher rate (74.41%),age group 26-45 years (22.16%) and 46-70 years (22.06%) (Figure 1). Male population undergoes indirect veneering than the female population which is about 62.80% (Figure 2), 11 teeth number is the most common tooth undergone for indirect veneering which is about 27.97% ( Figure 3). A2 shade

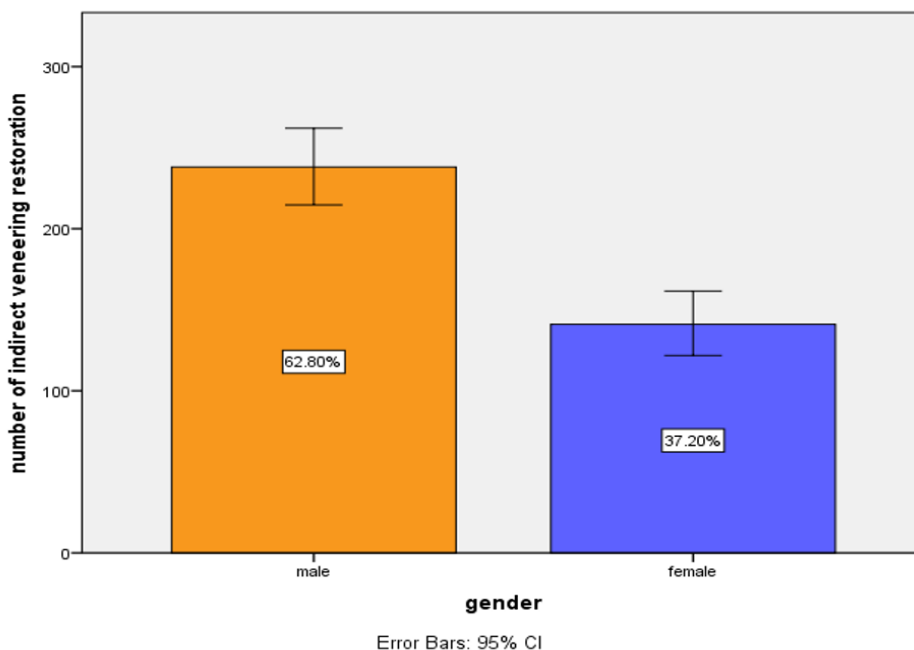


Figure 2: The bar graph of distribution of Gender among people who had indirect veneering. The Gender of patients were mentioned in X-axis which were categorized as female and males and the percentage of patients who received indirect veneering were mentioned in Y-axis. Of these, Male patients were at a higher rate (62.80%) than females (37.20%).

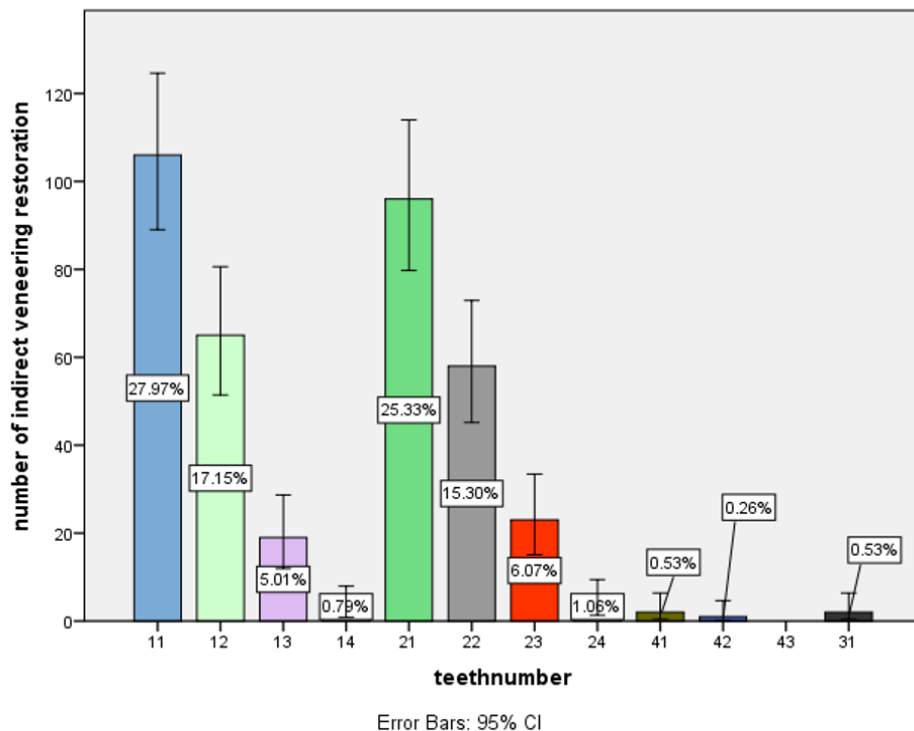


Figure 3: The bar graph of distribution of Teeth number among people who underwent indirect veneering. The Teeth number of patients was mentioned in the X-axis which were categorized as 11,12,13,14,21,22,23,24,41,42 and 43 and the percentage of patients who had indirect veneering were mentioned in Y-axis. Of these, teeth numbers 11 had patients at a higher rate (27.97%).

is most commonly used in indirect veneering which is about 47.23% (Figure 4). By comparing age and shade used in indirect veneering it is found to be statistically

significant (Figure 5). By comparing age and shade used in indirect veneering it is found to be statistically significant (Figure 6).

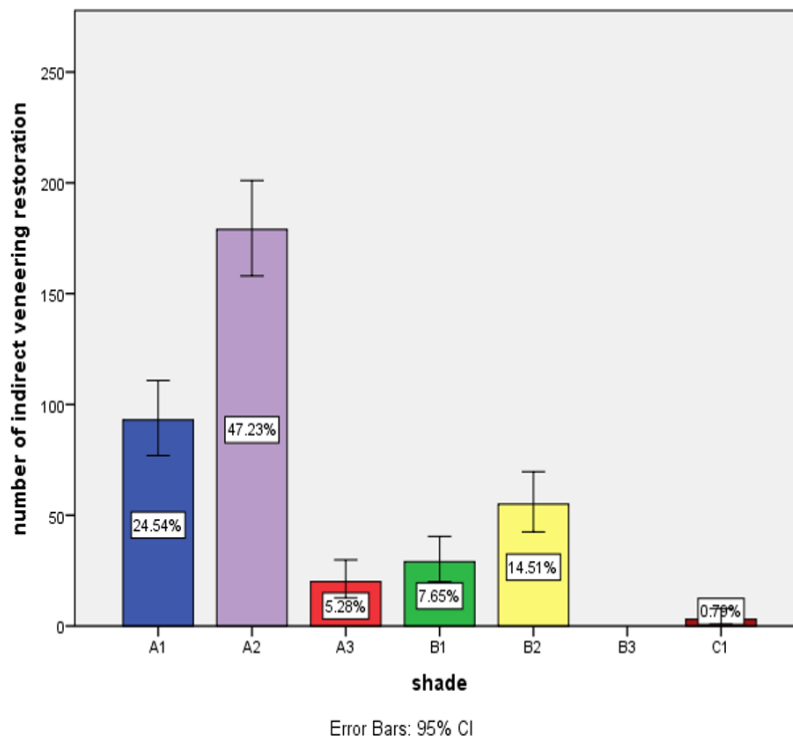


Figure 4: The bar graph of distribution of type of shade used for indirect veneering. The type of shade used were mentioned in X-axis which were categorized as A1,A2,A3,B1,B2,B3,C1 and the percentage of patients who used the shades mentioned in the Y-axis. Of these, A2 shade is most commonly used which is about 47.23%, A1 shade was 24.54%, B2 was 14.51% and B1 was 7.65%.

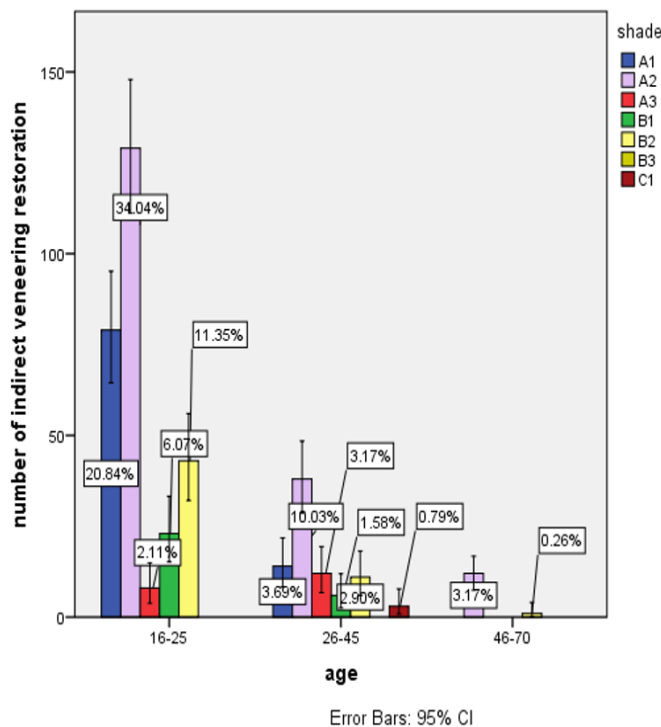
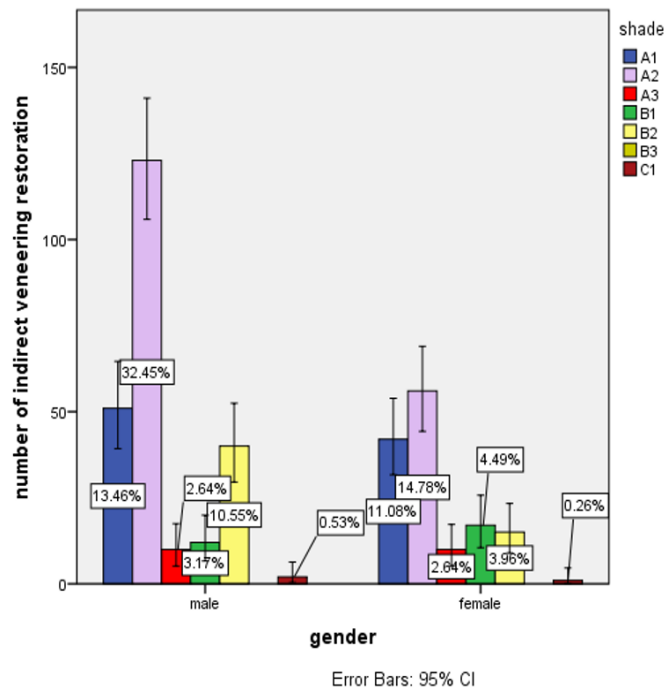


Figure 5 : The bar graph represents the association between type of shade used and age of patients who received indirect veneering where X-axis represents age with types of shade used and Y-axis represents the percentage of patients who received indirect veneering . A2 shade was used in a higher incidence among 16-25 years of age group people in association with the type of shade used . p-value >0.05(Chi-square value - 41.572a; P-value : 0.000). Hence, statistically significant.



**Figure 6:** The bar graph represents the association between type of shade used and gender of patients who received indirect veneering where X-axis represents gender with types of shade used and Y-axis represents the percentage of patients who received indirect veneering . A2 was used in a higher incidence among male population in association with the type of shade used. P-value >0.05 (Chi-square value - 14.614a; P-value: 0.012). Hence, it is statistically significant.

## DISCUSSION

According to Newton Fahal et al., [37] recent advances in composite materials, instrumentation, and chairside light-curing have generated renewed interest in the direct-indirect composite veneer technique given its advantages over directly-placed veneers. Modern composites, when correctly used, can achieve esthetics that match that of ceramics in many cases, including surface texture and shade matching and characterization.

According to Al-Halbi et al. [38] indirect veneers have undergone considerable improvement and refinement over the past few decades, and have now matured into a predictable restorative concept in terms of longevity, periodontal response and patient satisfaction. These veneer restorations provide a valid conservative alternative to complete coverage as they avoid aggressive dental preparation; thus, maintaining tooth structure.

According to Karishma Ravithar et al., [39] Veneers is a minimally invasive option for the treatment of discoloured and malformed teeth. The recent advancements in veneers and laminates in dentistry have given rise to an excellent alternative for a conservative approach for the teeth. It closely resembles the natural teeth and hence has good aesthetics. Its placement is a minimally invasive procedure and hence is widely accepted by patients. The recent advancements having good biocompatibility, high strength, durability and stain resistance has increased the demand for laminates in dentistry.

According to Preethika Babar et al., [40] significant advances in porcelain technology have permitted

increased versatility in its use as a restorative material. When combined with acid-etch bonding techniques, porcelain laminate veneers are a more conservative and highly esthetic alternative to full coverage restoration in appropriate clinical situations. Composite resins have a promising future in dentistry. The technology has progressed over the years, and bonding agents will ensure strong, long-lasting adhesion to tooth structure. However, ceramic materials such as E Max and monolithic Zirconia provide viable alternatives.

## CONCLUSION

Within the limits of the study, it was concluded that A2 shade was the most common material used during indirect veneering with male predilection. Furthermore studies to be done in a larger sample size for better results.

## ACKNOWLEDGEMENT

I sincerely thank my Guide, Mentor, Department of Research & IT Saveetha Dental College and Hospitals, Saveetha Institute Medical and Technical Sciences, Saveetha University for making me complete the research work.

## FUNDING

The present project is supported/funded/sponsored by Saveetha Institute of Medical and Technical Sciences, Saveetha Dental College and Hospitals, Saveetha University contributed by Southern Engineering Co Ltd.

## CONFLICT OF INTEREST

Nil.

## REFERENCES

- Milleding P, Örtengren U, Karlsson S. Ceramic inlay systems: Some clinical aspects. *J Oral Rehab* 1995; 22:571.
- Nordbø H, Rygh-Thoresen N, Henaug T. Clinical performance of porcelain laminate veneers without incisal overlapping: 3-year results. *J Dent* 1994; 22:342-345.
- Shaini FJ, Shortall ACC, Marquis PM. Clinical performance of porcelain laminate veneers. A retrospective evaluation over a period of 6.5 years. *J Oral Rehab* 1997; 24:553-559.
- Gresnigt MMM, Özcan M. Fracture strength of direct versus indirect laminates with and without fiber application at the cementation interface. *Dent Material* 2007; 23:927-933.
- Machado AN, Coelho-de-Souza FH, Rolla JN, et al. Direct or indirect composite veneers in anterior teeth: which method causes higher tooth mass loss? An *in vitro* study. *Gen Dent* 2014; 62:55.
- Miletic V. Dental composite materials for direct restorations. Springer 2017; 319.
- Felippe LA, Baratieri LN. Direct resin composite veneers: masking the dark prepared enamel surface. *Quintessence Int* 2000; 31:557-562.
- Rosentritt M, Sawaljanow A, Behr M, et al. Effect of tooth brush abrasion and thermo-mechanical loading on direct and indirect veneer restorations. *Clin Oral Invest* 2015; 19:53-60.
- Nalbandian S, Millar BJ. The effect of veneers on cosmetic improvement. *Br Dent J* 2009; 207:E3-E3.
- Gresnigt M, Ozcan M. Esthetic rehabilitation of anterior teeth with porcelain laminates and sectional veneers. *J Can Dent Assoc* 2011; 77:143.
- Trushkowsky RD. Esthetic oral rehabilitation with veneers: A guide to treatment preparation and clinical concepts. Springer Nature 2020; 411.
- Rada RE, Jankowski BJ. Porcelain laminate veneer provisionalization using visible light-curing acrylic resin. *Quintessence Int* 1991; 22:291.
- Elledge DA, Hart JK, Schorr BL. A provisional restoration technique for laminate veneer preparations. *J Prosthet Dent* 1989; 62:139-142.
- Magne P. Immediate dentin sealing: A fundamental procedure for indirect bonded restorations. *J Esthet Restor Dent* 2006; 17:144-154.
- Swift B, Walls AW, McCabe JF. Porcelain veneers: The effects of contaminants and cleaning regimens on the bond strength of porcelain to composite. *Br Dent J* 1995; 179:203-208.
- Cardash HS, Baharav H, Pilo R, et al. The effect of porcelain color on the hardness of luting composite resin cement. *J Prosthet Dent* 1993; 69:620-623.
- Muthukrishnan L. Imminent antimicrobial bioink deploying cellulose, alginate, EPS and synthetic polymers for 3D bioprinting of tissue constructs. *Carbohydr Polym* 2021; 260:117774.
- PradeepKumar AR, Shemesh H, Nivedhitha MS, et al. Diagnosis of vertical root fractures by cone-beam computed tomography in root-filled teeth with confirmation by direct visualization: A systematic review and meta-analysis. *J Endod* 2021; 47:1198-11214.
- Chakraborty T, Jamal RF, Battineni G, et al. A review of prolonged post-COVID-19 symptoms and their implications on dental management. *Int J Environ Res Public Health* 2021; 18.
- Muthukrishnan L. Nanotechnology for cleaner leather production: A review. *Environ Chem Lett* 2021; 19:2527-2549.
- Teja KV, Ramesh S. Is a filled lateral canal: A sign of superiority? *J Dent Sci* 2020; 15:562.
- Narendran K, Jayalakshmi, Sarvanan A, et al. Synthesis, characterization, free radical scavenging and cytotoxic activities of phenylvilangin, a substituted dimer of embelin. *Int J Pharm Sci* 2020; 82.
- Reddy P, Krithikadatta J, Srinivasan V, et al. Dental caries profile and associated risk factors among adolescent school children in an Urban South-Indian City. *Oral Health Prev Dent* 2020; 18:379-386.
- Sawant K, Pawar AM, Banga KS, et al. Dentinal microcracks after root canal instrumentation using instruments manufactured with different NiTi alloys and the SAF System: A systematic review. *Adv Sci Inst Ser E Appl Sci* 2021; 11:4984.
- Bhavikatti SK, Karobari MI, Zainuddin SLA, et al. Investigating the Antioxidant and Cytocompatibility of *Mimusops elengi* Linn extract over human gingival fibroblast cells. *Int J Environ Res Public Health* 2021; 18.
- Karobari MI, Basheer SN, Sayed FR, et al. An *in vitro* stereomicroscopic evaluation of bioactivity between Neo MTA Plus, Pro Root MTA, biodentine & glass ionomer cement using dye penetration method. *Materials* 2021; 14.
- Rohit Singh T, Ezhilarasan D. Ethanolic extract of *Lagerstroemia speciosa* (L.) Pers., induces apoptosis and cell cycle arrest in HepG2 cells. *Nutr Cancer* 2020; 72:146-156.
- Ezhilarasan D. MicroRNA interplay between hepatic stellate cell quiescence and activation. *Eur J Pharmacol* 2020; 885:173507.
- Romera A, Peredpaya S, Shparyk Y, et al. Bevacizumab biosimilar BEVZ92 versus reference bevacizumab in combination with FOLFOX or FOLFIRI as first-line treatment for metastatic colorectal cancer: A multicentre, open-label, randomised controlled trial. *Lancet Gastroenterol Hepatol* 2018; 3:845-855.
- Raj RK.  $\beta$ -Sitosterol-assisted silver nanoparticles

- activates Nrf2 and triggers mitochondrial apoptosis via oxidative stress in human hepatocellular cancer cell line. *J Biomed Mater Res A* 2020; 108:1899–908.
31. Vijayashree Priyadharsini J. *In silico* validation of the non-antibiotic drugs acetaminophen and ibuprofen as antibacterial agents against red complex pathogens. *J Periodontol* 2019; 90:1441.
32. Priyadharsini JV, Vijayashree Priyadharsini J, Smiline Girija AS, et al. *In silico* analysis of virulence genes in an emerging dental pathogen *A. baumannii* and related species. *Arch Oral Biol* 2018; 94:93–98.
33. Uma Maheswari TN, Nivedhitha MS, Ramani P. Expression profile of salivary micro RNA-21 and 31 in oral potentially malignant disorders. *Braz Oral Res* 2020; 34:e002.
34. Gudipaneni RK, Alam MK, Patil SR, et al. Measurement of the maximum occlusal bite force and its relation to the caries spectrum of first permanent molars in early permanent dentition. *J Clin Pediatr Dent* 2020; 44:423–428.
35. Chaturvedula BB, Muthukrishnan A, Bhuvanaraghan A, et al. Dens invaginatus: A review and orthodontic implications. *Br Dent J* 2021; 230:345–350.
36. Kanniah P, Radhamani J, Chelliah P, et al. Green synthesis of multifaceted silver nanoparticles using the flower extract of *Aerva lanata* and evaluation of its biological and environmental applications. *Chemistry Select* 2020; 5:2322.
37. Fahl N, Ritter AV. Composite veneers: The direct–indirect technique revisited. *J Esthet Restor Dent* 2021; 33:7-19.
38. R AH, Al-Halabi R. Indirect composite laminate veneers for upper anterior teeth diastema closure: A case report. *Int J Dent Oral Health* 2016; 1.
39. Ravinthar K, Jayalakshmi. Recent advancements in laminates and veneers in dentistry. *Res J Pharm Technol* 2018; 11:785.
40. Baby P, Mathew J, Joy J, et al. Indirect esthetic restorations in anterior dentition-A review. *Int J Sci Res* 2020; 9:580-584.