



Normal Cranial Sutures' Width in an Iranian Infant Population

Maryam Riahinezhad, Majid Hajizadeh*, Maryam Farghadani

Department of Radiology, Isfahan University of Medical Sciences, Isfahan, Iran

ABSTRACT

Background: The newborn skull is normally comprised of seven bones. The anatomy of the pediatric skull is a challenge, and the stages of its evolution are not easily recalled by radiologists. This comes from the variable nature and changing appearances of sutures over the normal developmental period. We aimed to investigate radiographically normative ranges of cranial suture widths in a representative sample of Iranian infants.

Material and Methods: In this cross-sectional study, a group of 302 high-resolution normal head CT scan of patients aged 0-12 months who had normal head contour and head circumference (Based on WHO growth chart) were reviewed.

Results: There is negative correlation between cranial suture width and age. Moreover, a statistically significant difference was seen between suture widths ($P < 0.0001$) and significant differences were seen among different age groups for all sutures. The average coronal and lambdoid sutures width were lower in women. There were no statistically significant difference between type of delivery and suture width ($P > 0.5$) the average normal cranial sutures' width for sagittal, coronal, lambdoid, and metopic sutures were 2.38 ± 1.04 , 2.06 ± 0.69 , 2.29 ± 0.65 , and 1.78 ± 0.88 mm, respectively. The average normal cranial suture widths for the sagittal, coronal, lambdoid, and metopic sutures were 2.38 ± 1.04 , 2.06 ± 0.69 , 2.29 ± 0.65 , and 1.78 ± 0.88 , respectively.

Conclusion: This study provides reference values for suture widths established by CT scan among a sample of Iranian infant population. Taken together, the findings of the present study show normal suture widths in a sample of Iranian infants less than 1 year by CT scans, and indicate that these findings are similar to previous reports.

Key words: Computed tomography, Cranial sutures widths, Sagittal suture, Coronal suture, Infants

HOW TO CITE THIS ARTICLE: Maryam Riahinezhad, Majid Hajizadeh*, Maryam Farghadani, Normal cranial sutures' width in an Iranian infant population, J Res Med Dent Sci, 2018, 6 (5):305-309

Corresponding author: Majid Hajizadeh

e-mail: Majid.ha65@gmail.com

Received: 17/10/2018

Accepted: 26/10/2018

INTRODUCTION

The newborn skull is normally comprised of seven bones; the paired frontal, temporal, and parietal bones, and the single occipital bone, and six sutures including the paired coronal and lambdoid sutures, and the single sagittal and metopic sutures [1,2]. The anatomy of the pediatric skull is a challenge, and the stages of its evolution are not easily recalled by radiologists. This comes from the variable nature and changing appearances of sutures over the normal developmental period [3]. The large sutures are seen in all infants less than 12 months of age and toddlers (1-4 years) and persist into adulthood [4]. Sutures are a type of fibrous joint that occurs only in the skull. The metopic suture, typically, is close at around 9-24 months; the sagittal suture, closes at around 22 years of age; the coronal suture closes at around 24 years; and the lambdoid suture close at around 26 years [5,6].

Clinically examination is routinely performed in newborn to evaluate the sutures status, which can be helpful and appropriate in the evaluation of pediatric patients presenting with skull deformity, diastasis of the sutures, seizures, trauma, or the concern for non-accidental trauma. Knowledge of anatomy and mechanism of closure of the sutures is crucial to avoid misdiagnosis of this defect as a focal cranial pathologic lesion. In the pediatric age group, numerous sutures have a variable appearance; so, the differentiation in this population is even more difficult [3,7].

Among the infant population, limited studies have described normal suture widths, and few studies have undertaken a systematic analysis to quantify normal suture widths based on CT. In the first study, Henderson et al. reported a large variation in the coronal and sagittal suture widths in infants by radiography [8]. To the best of our knowledge, no previous studies have documented the width of the normal coronal, sagittal, and lambdoid sutures on CT scans in children younger than 1 year in the Iranian population. Therefore, we aimed to assess the characteristics and width of normal sagittal, coronal, and lambdoid sutures in a sample of Iranian children younger than 1 year.

METHOD**RESULTS****Ethical approval and Patients study**

In this cross-sectional study, high-resolution CT scans for 302 normal patients aged 0 to 12 months, were reviewed. The subjects were selected among the patients who were scanned as part of a diagnostic procedure for suspected neurological disease, trauma, and developmental disorders or for screening purposes. The Ethics Committee of Isfahan University of Medical Sciences approved the study protocol before conducting the study.

The patients with normal head contour and a normal range of head circumference (based on the WHO growth chart) were included in our study. The head circumference was measured using a non-elastic tape measure held at the largest area of the infant's head above the eyebrows and ears.

Procedure

A review of CT imaging reports on the PACs (Picture Archiving and Communication System) identified patients with a normal CT of the head was performed; the study included head CTs conducted among patients 1 year of age or younger during September 2015 to December 2016 in Imam Hussein Children's Hospital. The preterm infants and infants who had undergone cranial surgery were excluded from the study.

The width of each of the cranial sutures (sagittal, coronal, lambdoid, and metopic) was measured. All measurements were made using the integrated calipers on the workstation software (GE Medical Systems), and had been performed with 2-slice CT scanner; with slice thickness of 5 mm and window width/level of 3000/550 HU.

Since there were no statistically significant variations found between right and left coronal and right and left lambdoid sutures, we used the mean values of these sutures in this study. The other characteristics of patients, including age, sex, indications for CT imaging, and delivery type were derived from individual medical records.

Statistical analyses

All statistical analyses were performed using SPSS software 23 (SPSS Inc., Chicago, IL, USA). The Shapiro-Wilk test was applied to evaluate the normal distribution of the quantitative variables. Quantitative and qualitative data are reported as mean \pm SD and number (percent), respectively. The one-way ANOVA with repeated measures, independent samples t-test and Spearman's correlation coefficient were used for statistical inference. All P values were two-tailed and statistical significance was set at the level of $P < 0.05$.

In this study, 302 medical records and normal brain CT scans were reviewed. 184 cases of trauma and 45 cases of non-accidental head injury were included in the study. Other indications for head CT in the population of children under study are shown in Table 1.

The mean \pm SD age of the studied population was 6.3 \pm 3.7 months, 56% (169 patients) were boys and 44% (133 patients) were girls. The mean \pm SD neonatal head circumference (HC) was 39.34 \pm 3.79 (range: 28.30-50.74 cm). Value of the total mean of lateral ventricle's (LV) frontal horn and Trigones of lateral ventricle were 4.65 \pm 1.89 and 8.03 \pm 1.99 mm, respectively.

Table 2 and Figure 1 show the distribution of demographics, baseline characteristics, and trends of LV and HC during the first year of life.

Table 3 shows the basic descriptive statistics of sagittal, coronal, lambdoid, and metopic sutures of children under study. There was a statistically significant difference among the suture widths (Kruskal-Wallis test; $\chi^2 \approx 130.261$ (df=3); $P < 0.0001$). The results of repeated measures analysis of variance show that there were statistically significant differences among different age groups for sagittal, coronal and lambdoid sutures (two-tailed P values between 0.002 and 0.010). Comparison of cranial sutures according to sex based on independent t test showed that the average coronal and lambdoid sutures' width were lower in the girls, though statistical significance was only seen for the coronal suture ($P = 0.042$). There was no statistically significant difference between type of delivery and sutures' width ($P > 0.05$).

Based on Spearman's correlation analysis, there was a negative correlation between cranial sutures' width and age. As shown in Table 4, the slight correlations (linear Spearman's correlation coefficients from 0.09 to 0.15) were not statistically significant at the 95% confidence interval in girls, but for male participants, these stronger correlations (Spearman's r_s ; from 0.21 to 0.33) were statistically significant (All P values < 0.007).

Table 1: Indications for head CT in the population of children under study

Indications for imaging	Number of head CTs	Percent (%)
Trauma	184	60.9
Non-accidental head injury	45	14.9
Seizure	41	13.6
Developmental disorder, nausea, vomiting	27	8.9
Other	5	1.7

Table 2: Descriptive patterns, trends and lateral ventricle of participant characteristics in the first 12 months of life by age

Age (month)	N	%	F/M	HC (cm)	Frontal horn (mm)	Trigones (mm)
1	26	0.09	13/13	34.00 ± 2.66	3.91 ± 1.29	7.46 ± 1.45
2	27	0.1	12/15	35.28 ± 2.31	4.62 ± 1.62	7.15 ± 1.94
3	26	0.09	18/8	36.21 ± 2.30	4.74 ± 1.29	7.95 ± 1.92
4	28	0.1	11/17	38.25 ± 2.47	4.61 ± 1.16	8.12 ± 1.66
5	26	0.09	11/15	39.30 ± 1.82	4.57 ± 1.20	7.38 ± 1.69
6	21	0.07	10/11	40.69 ± 2.06	5.58 ± 3.37	8.28 ± 2.42
7	30	0.11	17/13	40.39 ± 2.62	4.72 ± 2.12	7.91 ± 1.95
8	22	0.08	8/14	41.13 ± 1.64	5.23 ± 1.46	8.18 ± 1.26
9	14	0.05	6/8	42.11 ± 2.30	4.59 ± 1.67	8.61 ± 2.15
10	21	0.07	8/13	42.79 ± 1.62	5.29 ± 2.31	9.02 ± 1.71
11	16	0.06	3/13	42.23 ± 1.75	4.29 ± 1.93	7.76 ± 1.91
12	25	0.09	8/17	43.55 ± 1.22	4.35 ± 1.67	9.09 ± 1.42

Data are presented as Number and Mean ± SD.

N: Number of head CT scans; F: Female; M: Male; HC: Head circumference; cm: Centimeter; mm: Millimeter.

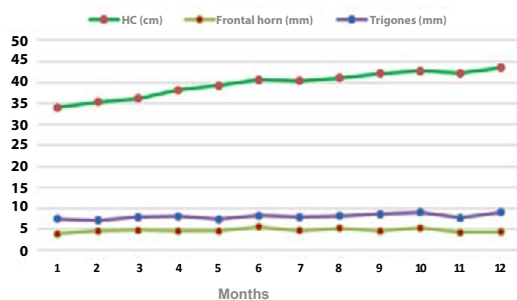


Figure 1: Trends of frontal horn (mm), trigones (mm) and head circumference change (cm) in studied population at the first 12 months of life by age

DISCUSSION

Recently, the issue of using emergency departments for pediatric evaluation has been raised leading to increasing number of neonates and infants to undergo CT imaging of the head for various reasons. Therefore, valuable information about normal suture widths in infants can be helpful in the assessment of CT scans and prevent the concern for suture fracture, diastasis or abnormality. This study expands on the evaluation of sutures widths

by CT scans in infants throughout the first year of life. Trauma is the main reason for undergoing CT imaging of the head in the infants in our study. Our results indicate that the average width of the coronal suture is 2.37 mm at age of <2 months, narrowing significantly to 1.67 mm by 12 months of age. The average width of the sagittal suture is 2.76 mm at age <2 month, narrowing significantly to 1.63 mm at 12 months. The lambdoid suture is significantly narrow in 2.57 at age <2 months to 1.86 mm at 12 months of age. The metopic suture is 1.96-1.62 at ages <2 to 12 months of age, respectively. Also, the coronal suture in male infants is significantly larger than female infants but other sutures are similar in size between males and females. In sub-group analyses, a significant relation was found between sutures widths and age among male infants; but in female students this relation was not statistically significant. This information about normal suture widths in infants at the first year of life based on CT scans can be helpful for radiologists in the assessments of scans.

To the best of our knowledge, the only previous study in the literature to report the appearance of coronal and

Table 3: The mean of sagittal, coronal, lambdoid and metopic sutures width in children under study and their association with age, sex and delivery methods

Characteristics	N	Cranial sutures			
		Sagittal (n=295)	Coronal (n=275)	Lambdoid (n=296)	Metopic (n=180)
Suture width	302	2.38 ± 1.04	2.06 ± 0.69	2.29 ± 0.65	1.78 ± 0.88
Age group (month)					
≤ 2	53	2.76 ± 1.84	2.38 ± 1.11	2.51 ± 0.94	1.96 ± 0.94
3-4	54	2.52 ± 1.06	2.09 ± 0.55	2.39 ± 0.58	1.90 ± 1.18
5-8	99	2.32 ± 0.65	1.98 ± 0.53	2.33 ± 0.62	1.61 ± 0.57
9-12	76	2.19 ± 0.62	1.93 ± 0.55	2.09 ± 0.44	1.62 ± 0.62
>12	6	1.63 ± 0.27	1.67 ± 0.32	1.86 ± 0.21	-
‡P-value	---	0.01	0.004	0.002	0.138
Gender					
Girl	133	2.38 ± 1.01	1.96 ± 0.60	2.24 ± 0.61	1.76 ± 0.53
Boy	169	2.38 ± 1.08	2.14 ± 0.75	2.33 ± 0.67	1.80 ± 1.12
\$P-value	---	0.976	0.042	0.229	0.744
Delivery type					
Vaginal delivery	123	2.43 ± 1.02	2.06 ± 0.67	2.32 ± 0.63	1.70 ± 0.66
C-Section	111	2.46 ± 1.23	2.05 ± 0.69	2.24 ± 0.69	1.85 ± 1.17
\$P-value	---	0.863	0.867	0.398	0.342

Data are presented as mean ± SD; Calculated P-values derived from ‡One-way ANOVA with repeated measures, and \$Independent samples t-test; Unit of measurement: mm

Table 4: Ranges of Cranial sutures width by sex, and its correlation (r) with age

Gender	n	Cranial sutures range							
		Sagittal	r [P]	Coronal	r [P]	Lambdoid	r [P]	Metopic	r [P]
Female	133	1.00-10.80 (9.80)	-0.151 [0.092]	0.90-5.30 (4.40)	-0.093 [0.320]	1.10-5.20 (4.10)	-0.129 [0.152]	1.00-4.10 (3.10)	-0.011 [0.924]
Male	169	1.00-9.50 (8.50)	-0.214 [0.007]	0.00-6.50 (6.50)	-0.257 [0.002]	1.10-5.60 (4.50)	-0.287 [<0.001]	0.00-9.00 (9.00)	-0.331 [0.002]

r: Correlation Coefficient; P: p-value; Data are presented as Min-Max (range) and correlation with age [p-value]; All P-values calculated by Spearman Correlation

sagittal sutures in normal infants on CT was done by Mitchell et al. They evaluated the size of cranial sutures on CT scans in 483 patients between 1 and 395 days of age [7]. They found that the proximal suture widths for the sagittal suture widths was 5, 2.5, and 1.1 mm at zero, first, and 12 months of age, respectively. They reported a significant difference between mean proximal sagittal suture width at 0 months with 1 month of age, and 1 month with 12 months of age. Similar to the mentioned study, the mean sagittal suture widths in our study was 2.57 for infants <2 months of age, but at 12 months of age it was 1.63 mm. Also, similar to Mitchell et al. [7] results, we found a significant difference between mean sagittal suture width at <2 months and 12 months of age. The proximal coronal suture widths in Mitchell et al's., study was 2.5, 1.3, and 0.8 mm at zero, first, and 12 months of age, respectively. The mean coronal suture width in our study was 2.38 and 1.67 at <2 and 12 months of age, which was similar to the mentioned study for 1 month of age and was higher for 12 months of age. They reported a significant difference between mean suture width at 0 month and 1 month of age, but they did not find a significant reduction in the mean suture width between 1 and 12 months of age. Unlike Mitchell et al. results, we found a significant difference between mean coronal suture width at <2 and 12 month of age. The differences between the two studies for suture widths at 12 months of age may be explained by the lower number of patients who were 12 months old in our study. Our findings as well as Mitchell et al. study provided appropriate information about coronal and sagittal suture widths in infants lower than 12 months of age based on CT scans for assessments of infants' skull [7].

In another previous study, the researchers report the appearance of cranial sutures in 53 infants younger than 1 year on MRI scans [9]. They reported that the mean coronal suture widths in their studied infants was 1.2 mm; being 1.4 mm for sagittal suture, and 1.3 mm for lambdoid suture. These findings are different from that find in our study, the sutures widths in the present study were higher than the mentioned study at a lower age but are nearly comparable at a higher age of about 12 months. The difference between both studies can be explained by the difference in assessment method; we reported our results base on CT scans, while in the mentioned study, the findings were based on MIR scans.

In a study by Soboleski et al., 50 infants aged 0 to 5 months undergoing brain sonography were assessed to examine the cranial suture width of the coronal, sagittal, and lambdoid sutures [10]. They reported that the mean coronal, sagittal, and lambdoid suture widths were 0.89, 0.93, and 0.96, respectively. Also, they reported that sutures widths were not correlated with age in their studied population. Unlike the mentioned study, we found a significant negative correlation between age and suture widths in infants under 1 year, also the mean of all sutures widths in our study are higher than that reported

in the previously mentioned study. The differences between these findings can be due to different sample sizes (50 infants in Soboleski et al. study versus 302 infants in the present study) and assessment method (sonography in Soboleski et al. study and CT scans in our study).

Our study had some limitations. First, we did not separate the studied scans by age 0, and 1 month, and we assessed subjects who were 0-2 months or other age groups. A previous study has suggested that the mean suture widths rapidly decrease in the first month of life [7]. Second, low number of subjects in a higher age group in our study, might have reduced the power of the study to assess the differences between mean suture widths in infants with respect to age groups.

CONCLUSION

Taken together, the findings of the present study show normal suture widths in a sample of Iranian infants less than 1 year by CT scans, and indicate that these findings are similar to previous reports. Also, we found a significant negative correlation between age and sutures widths in infants under 1 year, where mean suture widths rapidly decreased in the first year of life in infants. However, data about normal suture widths in infants during the first of life by CT scans are limited to two studies, the importance of the distinction between normal sutural anatomy and abnormalities, shows the necessity of further studies to evaluate sutures widths and closes in infants under 1 year based on CT scans as the frequent methods to assess infants' head problems.

CONFLICT OF INTEREST

All authors declare that there is no conflict of interest.

REFERENCES

1. Glass RB, Fernbach SK, Norton KI, et al. The infant skull: A vault of information. *Radiographics* 2004; 24:507-22.
2. Miura T, Perlyn CA, Kinboshi M, et al. Mechanism of skull suture maintenance and interdigitation. *J Anat* 2009; 215:642-55.
3. Idriz S, Patel JH, Ameli Renani S, et al. CT of normal developmental and variant anatomy of the pediatric skull: Distinguishing trauma from normality. *Radiographics* 2015; 35:1585-601.
4. Nakahara K, Utsuki S, Shimizu S, et al. Age dependence of fusion of primary occipital sutures: A radiographic study. *Child's Nervous Sys* 2006; 22:1457-9.
5. Amiel-Tison C, Gosselin J, Infante-Rivard C. Head growth and cranial assessment at neurological examination in infancy. *Dev Med Child Neurol* 2002; 44:643-8.
6. Vijay Kumar AG, Agarwal SS, Bastia BK, et al.

- Fusion of skull vault sutures in relation to age-a cross sectional postmortem study done in 3rd, 4th & 5th decades of life. *J Forensic Res* 2012; 3:2145-57.
7. Mitchell LA, Kitley CA, Armitage TL, et al. Normal sagittal and coronal suture widths by using CT imaging. *AJNR Am J Neuroradiol* 2011.
 8. Henderson SG, Sherman LS. The Roentgen anatomy of the skull in the newborn infant. *Radiology* 1946; 46:107-18.
 9. Eley KA, Sheerin F, Taylor N, et al. Identification of normal cranial sutures in infants on routine magnetic resonance imaging. *J Craniofac Surg* 2013; 24:317-20.
 10. Soboleski D, McCloskey D, Mussari B, et al. Sonography of normal cranial sutures. *AJR Am J Roentgenol* 1997; 168:819-21.