

# Omphalocele in Newborn: A Case Report

Madhuri Shambharkar\*, Kamini Rodge, Achita Sawarkar, Jaya Khandar, Vaishali Tembhare, Sheetal Sakaharka

Department of Community Health Nursing, Datta Meghe Institute of Medical Sciences, Wardha, Maharashtra, India

## ABSTRACT

**Introduction:** Omphalocele, commonly known as exomphalos or omphalocele, is an uncommon abdominal wall abnormality. Starting in the sixth week of development, fast gut elongation and increasing hepatic volume restrict an area within the abdomen, pushing loops of intestines exiting the abdominal cavity. Around 15% of live children with omphalocele are affected by chromosome abnormalities.

**Clinical findings:** Swelling over abdomen, protrusion above umbilicus.

**Diagnostic evaluation and blood test:** HB-19.4%, Total RBCs Count-5.57 million/cubic mm, Total WBCs Count-22900/cubic mm, Total Platelet Count-2.62/microliter, RDW-17.6%, MCV-105.7%

**Peripheral smear:** RBCs-Normocytic Normochromic, Platelets-Adequate to smear, TLC-22.9 cells/cu mm, ANC-17.175 cells/cu mm, No band forms seen.

**Histopathology report:** Omphalocele sac with umbilical cord, Content of omphalocele sac.

**Operation:** Omphalocele repair done.

**Therapeutic intervention:** Inj. Piptaz 260 mg IVx BD, Inj. Amikacin 40 mg IVx OD, Inj. Mertrogyl 20 mg IVx TDS, Glycerin suppository x TDS.

**Outcome:** After treatment and surgery, the new-born show improvement. No complaint of hypoglycaemia is seen. No sign of respiratory distress.

**Conclusion:** This patient was hospitalised in Paediatric ward with an omphalocele and a complaint of protrusion above the umbilical cord. His health began to improve when he received proper therapy that is repair of omphalocele done.

**Key words:** Omphalocele, Gut elongation, Omphalocele sac, Umbilical cord protrusion

**HOW TO CITE THIS ARTICLE:** Madhuri Shambharkar, Kamini Rodge, Achita Sawarkar, Jaya Khandar, Vaishali Tembhare, Sheetal Sakaharka, Omphalocele in Newborn: A Case Report. J Res Med Dent Sci, 2022, 10(5): 81-86.

**Corresponding author:** Madhuri Shambharkar

**E-mail:** Mnnaik91@gmail.com

**Received:** 23-Feb-2022, Manuscript No. JRMDs-22-43823;

**Editor assigned:** 25-Feb-2022, Pre QC No. JRMDs-22-43823 (PQ);

**Reviewed:** 11-Mar-2022, QC No. JRMDs-22-43823;

**Revised:** 24-Apr-2022, Manuscript No. JRMDs-22-43823 (R);

**Published:** 2-May-2022

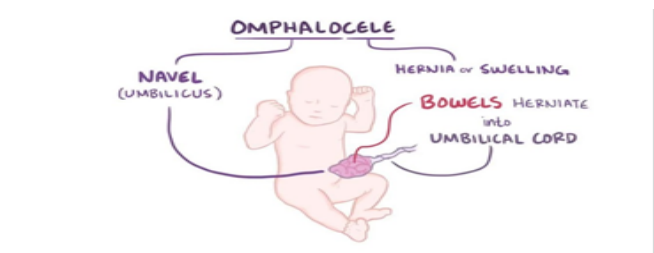
## INTRODUCTION

An omphalocele is caused by the occurrence of intestine or because umbilical cord contains other abdominal viscera (such as the stomach and liver).

Exomphalos is one in four thousand newborns and is associated with significant death risk (25%) and severe heart defects (50%) and tube defects (40%) as well as bladder exstrophy and Beckwith-Wiedemann syndrome. Around 15% of live children with omphalocele are affected by chromosome abnormalities. Around 30% of newborns born with an exomphalos also have other hereditary issues [1].

Omphalocele is thought to affect 2-3 out of every 10,000 pregnancies. During 6 to 10 weeks of pregnancy, a baby's intestines get longer and push out from the belly into the umbilical cord. The intestines then go back into the belly by week 11. If this does not happen, an omphalocele occurs. An omphalocele can be small,

with only some of the intestines outside of the belly, or it can be large or "giant", with many organs outside of the belly [2]. Baby's with omphalocele have developed other problem like heart defects and other chromosomal abnormalities occur in 30% of children [3] (Figure 1).



**Figure 1: Diagrammatic Representation of Omphalocele.**

This condition is occurring due to be a deficiency in the normal physiological umbilical herniation of abdominal content. Targeted prenatal ultrasonography, echocardiography to identify linked deadly heart malformations, and lastly karyotyping, which is frequently connected with chromosomal abnormalities, is the three key diagnostic tests [4]. Complications can arise before, during, or after surgery. Exomphalos can rupture both before and after delivery. For big Omphalocele, there may

be liver injuries upon delivery. As a metabolic extract, omphalocele may function, during therapy, to disrupt the nitrogen balance and cause both hypothermia and failures to thrive.

**CASE PRESENTATION**

**Patient identification:** A male neonates admitted with a complaint of swelling over the umbilicus and fever. A neonate is of 2.6 kg at the time of admission and his length was 48 cm.

**Clinical finding:** Protrusion above umbilicus seen after birth of baby.

**Etiology:** During development, Omphalocele is caused by the bowels returning to the abdomen in a twisted state. Omphalocele is thought to be caused by a genetic condition called Edward's syndrome (trisomy 18) or Patau syndrome in some cases (trisomy 13). Omphalocele are another feature of Beckwith-Wiedemann syndrome [4]. Exomphalos is strongly linked to chromosomal abnormalities, which are now being investigated to determine the disease's genetic basis [5].

**Physical examination:** Baby's weight was 2.4 kg. Vital signs were normal. There is no other abnormality was found in head to toe examination, instead of abdominal swelling, protrusion above umbilicus. No sign of respiratory distress. The child is lean and thin and having dull look. He was weak.

**Diagnostic evaluation:** Blood test: HB-19.4%, Total RBCs Count-5.57 million/cubic mm, Total WBCs Count-22900/cubic mm, Total Platelet Count-2.62/microleter, RDW-17.6%, MCV- 105.7%. Peripheral Smear: RBCs-Normocytic Normochromic, Platelets-Adequate to smear, TLC -22.9 cells/cumm, ANC-17.175 Cells/cumm, No band forms seen. In ultrasonography findings in the sac there was liver attached with herniating content.

**Histopathology report**

- Omphalocele sac with umbilical cord.
- Content of Omphalocele. Sac measuring 4 cm in length. Received whitish, greyish sac attached to umbilical cord. Single, globular, greyish tissue piece measuring 0.5 cm in length.

**Therapeutic intervention:** Inj. Piptaz 260 mg IV x BD, Inj. Amikacin 40 mg IV x OD, Inj. Mertrogyl 20 mg IV x TDS, Glycerin suppository x TDS.

**Surgical management:** The patient underwent surgery after consulting responsible physicians and paediatricians. Repair of Omphalocele was done [6].

**Nursing management**

**Pre-operative**

Table 2: Nursing diagnosis: Low nutritional pattern less than body requirement related to disease condition.

S. no	Nursing Interventions	Rationale
1	Assess the level of pain then record and report it to doctor.	To know the level of pain and frame further interventions.
2	Consult and co-ordinate with health care team members of various department included in the case.	To confirm the final diagnosis with staging and prepare nursing diagnosis to provide effective care.
3	Administer the analgesics as prescribed by the doctors.	To reduce pain.

Table 3: Nursing diagnosis: Acute pain in abdomen related to surgical incision.

S. no	Nursing Intervention	Rationale
1	Monitor the weight of the newborn.	To collect the baseline data.
2	Insert nasogastric feed to the baby.	To maintain nutrition.

**Post-operative**

Table 3: Nursing diagnosis: Acute pain in abdomen related to surgical incision.

S. no	Nursing Intervention	Rationale
1	Obtain the level of pain on pain-scale	To prepare the post-operative nursing intervention on pain.
2	Provide comfortable position to the patient.	To induce comfort and rest.
3	Administer the prescribed medications by the physicians.	To help the patient cure fast and also to reduce pain.



