

# A Study on Fissure in Ano-Comparison between Topical Glyceryl Trinitrate (0.2%) and Lateral Anal Sphincterotomy

Sabarisan<sup>1</sup>, Gopalsamy Santhanam Prabudoss<sup>2\*</sup>

*1Department of General Surgery, Sree Balaji Medical College & Hospital Affiliated to Bharath Institute of Higher Education and Research, Chennai, Tamil Nadu, India*

*2Department of Surgical Gastroenterology, Sree Balaji Medical College & Hospital, Bharath University*

## ABSTRACT

These patients were broadly divided into two groups of 52 each who were treated by medical and surgical methods respectively by non-randomised control study. In this study, males were commonly affected than females. The most common age group were 41-50yrs. Fissure in ano is rare in children and old age. Majority of the patients presented with pain during defecation. Constipation was the major predisposing factor among all cases. Most of the fissures were located in the posterior midline. Most of the patients with fissures of long duration had sentinel skin tag and hypertrophied papilla. Anterior fissures were slightly more common in females. Two patients were IDV+ and one patient with history of tuberculosis had atypical lateral fissures.

**Key words:** Anterior fissure, Papilla, Defecation

**HOW TO CITE THIS ARTICLE:** R Sabarisan, Gopalsamy Santhanam Prabudoss, A Study on Fissure in Ano-Comparison between Topical Glyceryl Trinitrate (0.2%) and Lateral Anal Sphincterotomy, J Res Med Dent Sci, 2021, 9(9): 16-17

**Corresponding author:** Gopalsamy Santhanam Prabudoss  
**e-mail** ✉: editor.pubs@gmail.com  
**Received:** 16/07/2021  
**Accepted:** 02/09/2021

## INTRODUCTION

Anal fissure like a crack or ulcer found on the squamous lining of the anal canal this can be from acute to chronic, affecting both the sexes of any age group [1-3]. This study aims to determine the etiological factors, clinical features position of fissures, clinical presentations, and Comparative study of topical GTN (0.2%) over Lateral Internal anal sphincterotomy. Complications associated with medical and surgical management.

## METHODOLOGY

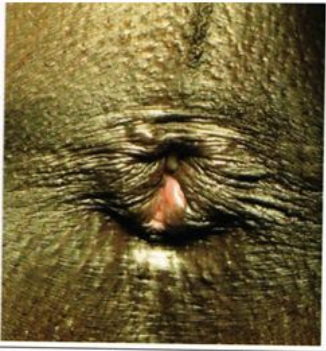
These patients were broadly divided by simple random sampling into two groups of 52 patients each who were managed by medical and surgical methods and were allotted alternatively to each group. For all these patients clinical examinations and routine investigations were done, which also include blood for sugar, urea and serum for Creatinine and ECG. Chest X ray was taken for all cases. Patients were observed for expected complications. Patients were discharged on 5th day. They were asked to follow up in outpatient department every weekly for one month.

## RESULTS AND DISCUSSION

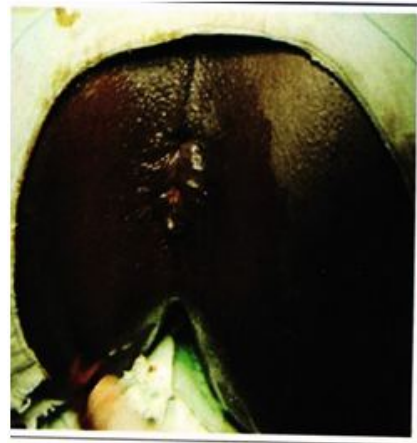
Majority of these patients had history of pain during defecation and bleeding per rectum. Other symptoms were swelling in the perianal region and retention of urine. Majority of the patients who were examined by digital rectal examination had posterior fissure in ano. Minority of patients had anterior fissure which is more common with females.

Lateral fissure was seen in few patients, Majority of patients who had fissure for longer duration had sentinel skin tag along the lower part of fissure and hypertrophied papilla in the upper part. All patients were put on 0.2% Glyceryl Trinitrate ointment twice daily topically after sitz bath. 38 out of 52 patients had relief of symptoms, which accounts to 70.4% of patients who were treated medically.

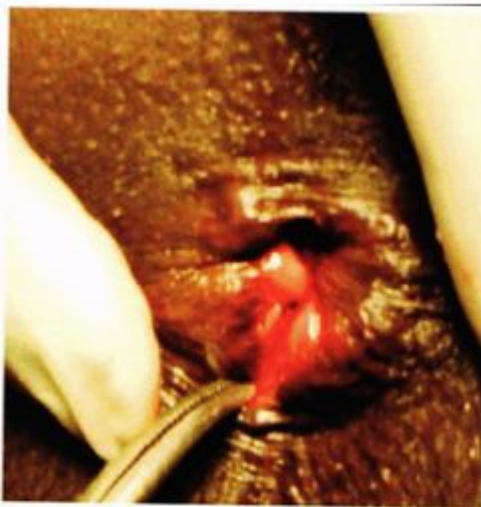Other patients had persistent pain and complications like headache. Most of the surgical complications subsided within two weeks and patient had complete relief of symptoms. 6 out of 52 patients treated surgically did not turn up for follow up. These results are in concurrence with previous study results (Figures 1 and 4) [4-10].



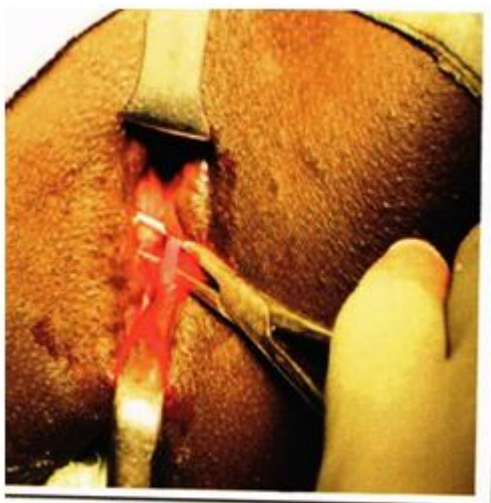
**Figure 1: Open lateral anal sphincterotomy: Before surgery.**



**Figure 4: After completion of sphincterotomy.**



**Figure 2: Open lateral anal sphincterotomy: Posterior assure in ANO.**



**Figure 3: Internal sphincter being hooked out before division.**

**REFERENCES**

1. Goligher J. Surgery of the anus, rectum and colon. London: BalliereTindall 1984; 170-91.
2. Hoffmann DC, Goligher JC. Lateral subcutaneous internal sphincterotomy in treatment of anal fissure. Br Med J 1970; 3:673-5.
3. Lund JN, Scholefield JH. A randomised, prospective, double-blind, placebo-controlled trial of glyceryltrinitrate ointment in treatment of anal fissure. Lancet 1997; 349:11-4.
4. Bacher H, Mischinger HJ, Wergartner G, et al. Local nitroglycerin for treatment of anal fissures: An alternative to lateral sphincterotomy? Dis Colon Rectum 1997; 40:840-5.
5. Goligher J. Surgery of the anus, rectum and colon. London: BalliereTindall 1984; 170-91.
6. Hoffmann DC, Goligher JC. Lateral subcutaneous internal sphincterotomy in treatment of anal fissure. BrMed J 1970; 3:673-5.
7. Lund JN, Scholefield JH. A randomised, prospective, double-blind, placebo-controlled trial of glyceryltrinitrate ointment in treatment of anal fissure. Lancet 1997; 349:11-4.
8. Bacher H, Mischinger HJ, WergartnerG, et al. Local nitroglycerin for treatment of anal fissures: an alternative to lateral sphincterotomy? Dis Colon Rectum 1997; 40:840-845.
9. Lund JN, Armitage NC, Scholefield JH. Use of glyceryltrinitrate ointment in the treatment of anal fissure. Br J Surg 1996; 83:776-777.
10. Libertiny G, Knight JS, Farour R. Randomised trial of tropical 0.2% glyceryltrinitrate and lateral internal sphincterotomy for the treatment of patients with chronic and fissure: long-term follow-up Eur J Surg 2002; 168:418-421.