

## Correlation of Placental Morphometry with Fetal Outcome in Preeclamptic Pregnancies

A Prathiba<sup>1</sup>, Dinisha Einstien<sup>2\*</sup>, Sudhakar R<sup>1</sup>, Saraswathi M<sup>3</sup>

<sup>1</sup>Department of Pathology, Panimalar Medical College, Hospital and Research Institute

<sup>2</sup>Department of Pathology, Chettinad Hospital and Research Institute

<sup>3</sup>Department of Pathology, Sri Muthukumaran Medical College Hospital and Research Institute

### ABSTRACT

*Introduction: Placental examination in a problematic pregnancy is of prime importance, in yielding valuable information about the duration and nature of the process that occurred throughout the pregnancy. This includes a thorough and thoughtful gross and morphometric examination, careful sectioning and clarity of the basic microscopic findings along with the various changes. Reduced placental perfusion happens to be the unique feature of placenta, resulting in preeclampsia. The placenta is also called the mirror of intrauterine fetal experience and remains the best record of every infant's prenatal experience. The pathological changes in the placenta adversely affect the fetal outcome. This study is an attempt to observe and compare the morphometric measurements of normal and preeclamptic placentae and to correlate the same with fetal outcome.*

*Aim: The aim of this study is to compare and analyze the placental morphometry in normal and hypertensive pregnancies and to correlate the fetal outcome with morphometric findings of placenta.*

*Materials and Methods: In this prospective study a total of 200 placentae were examined. The study group contained 100 pre-eclamptic placentae from singleton pregnancies and the control group contained 100 placentae from singleton normotensive pregnancies. The corresponding fetal birth weight and APGAR scores were also recorded. The placenta was then observed in fresh state and weighed. The placental disc measurements were taken. The placental surface area and placental volume were calculated. The placental morphometry was then compared with the fetal outcome. All statistical analyses were done with IBM SPSS software version 28.*

*Result: We observed that with increasing severity of preeclampsia, there is a significant decrease in the placental weight, volume and surface area and corresponding reduction in the mean fetal birth weight and fetal outcome.*

*Conclusion: We suggest that inclusion of in-utero measurement of placental volume in routine monitoring of fetal wellbeing in preeclamptic pregnancies will help in better management of at risk fetus.*

**Key words:** Placental morphometry, Preeclamptic pregnancies, Hypertension, Fetal outcome, Low birth weight, APGAR

**HOW TO CITE THIS ARTICLE:** A Prathiba, Dinisha Einstien, Sudhakar R, Saraswathi M, Correlation of Placental Morphometry with Fetal Outcome in Preeclamptic Pregnancies, J Res Med Dent Sci, 2022, 10(8):273-278.

**Corresponding author:** Dinisha Einstien

**e-mail** ✉: dr.dinieins@gmail.com

**Received:** 21-July-2022, Manuscript No. JRMDs-22-64555;

Editor assigned: 22-July-2022, **PreQC No.** JRMDs-22-64555(PQ);

**Reviewed:** 08-August-2022, QC No. JRMDs-22-64555(Q);

**Revised:** 12-August-2022, Manuscript No. JRMDs-22-64555(R);

**Published:** 19-August-2022

### INTRODUCTION

Placental pathology has undeniably received much less attention by medical professionals. Placental evaluation has proved to be of enormous value in numerous cases of perinatal death, unusual disorders of mother or

infant, gestational complications, problems in perinatal diagnosis and in multiple pregnancies [1,2]. Placental examination in a problematic pregnancy is of prime importance, in yielding valuable information about the duration and nature of the process that occurred throughout the pregnancy. This includes a thorough and thoughtful gross and morphometric examination, careful sectioning and a clarity of the basic microscopic findings along with the various changes including the whole list of pathologic processes [3,4]. The incidence of preeclampsia in India is 1.5%. It is a leading cause of maternal mortality and important factor for fetal wastage [5]. It is long known that placenta is the necessary component for the genesis of preeclampsia. Reduced placental perfusion happens to be the unique feature

of placenta, resulting in preeclampsia. The placenta is also called the mirror of intrauterine fetal experience and remains the best record of every infant's prenatal experience. Literature reveals that deleterious effects on the placenta are exerted by the preeclampsia-eclampsia syndrome. Macroscopically, preeclamptic placenta is found to be lesser in weight, diameter and thickness along with an increase in occurrence of abnormal shape, cord insertion and diminished fetoplacental ratio. Preeclamptic placentae also have an increase in the incidence of retro placental hematoma and infarction. Taken together, all the placental changes share a direct correlation to the severity and duration of the disease process. The pathological changes in the placenta adversely affect the fetal outcome. Thus, there arises a need for thorough examination of placenta. This study is an attempt to observe and compare the morphometric measurements of normal and preeclamptic placentae and to correlate the same with fetal outcome.

### Aims and objectives

The aim of this study is to compare and analyze the placental morphometry in normal and hypertensive pregnancies and to correlate the fetal outcome with morphometric findings of placenta.

### MATERIALS AND METHODS

In this prospective study a total of 200 placentae were examined. The study group contained 100 preeclamptic placentae from singleton pregnancies and the control group contained 100 placentae from singleton normotensive pregnancies. All the placentae were received shortly after delivery and washed in running tap water to remove the blood clots. Meanwhile the corresponding fetal birth weight and APGAR scores were also recorded. The placenta was then observed in fresh state, the membranes, cord and extraneous clots were removed and weight was recorded. The placental disc measurements were taken.

The placental surface area and placental volume were calculated using standard formulae.

Placental surface area ( $\text{cm}^2$ ) =  $(\pi \times \text{largest diameter} \times \text{shortest diameter}) / 4$ .

Placental volume ( $\text{cm}^3$ ) = surface area  $\times$  thickness at center.

All statistical analyses were done with IBM SPSS software version 20.

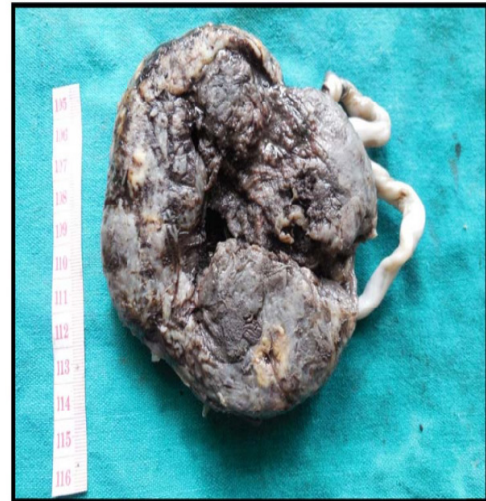### RESULTS

The comparison of placental morphometry with the severity of pre-eclampsia is shown in Table 1.

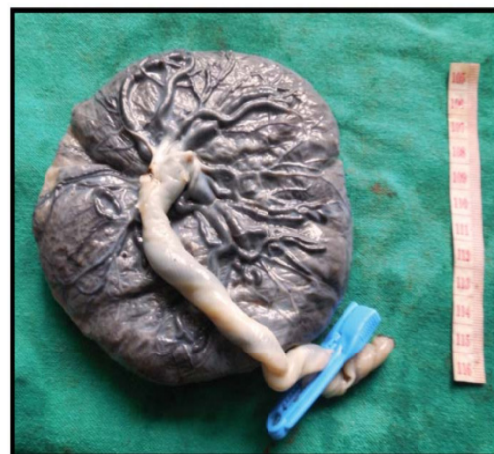
In this study, there is a negative correlation between severity of preeclampsia and the placental morphometric features like placental weight, volume and surface area (i.e.) with increasing severity of preeclampsia, there is a significant decrease in the placental weight, volume and

**Table 1: Correlation of placental morphometry with severity of preeclampsia in study group.**

	Placental weight	Placental volume	Placental surface area
Blood Pressure	-0.197	-0.159	-0.132



**Figure 1: Retro placental hematoma.**



**Figure 2: Small pre-eclamptic placenta.**

surface area. The incidence of retro placental hematoma (Figure 1) (case=26, control=2) and infarction (case=44, control=5) is significantly raised in the study group in comparison to control group. But, there is no significant difference in the occurrence of sub chorionic fibrin (case=3, control=6) and calcification (case=17, control=15) between the two groups. In the preeclamptic group, there was an increase in the mean no. of areas/lpf of syncytial knot formation, cytotrophoblastic cellular proliferation, villous fibrinoid degeneration, villous stromal fibrosis and irregular thickening of TBM (case=70.3%, control=29.7%) compared to the control group.

The comparison of placental morphometry with the fetal birth weight between the study group and control group is shown in Table 2. A statistically significant reduction in mean placental weight, surface area and volume was

**Table 2: Comparison of placental morphometry and fetal birth weight.**

	CASE (mean $\pm$ S.D)	CONTROL (mean $\pm$ S.D)	p - value
Placental Weight (gms)	421.8 $\pm$ 120.09	461.75 $\pm$ 99.08	0.011
Placental Surface Area (sq.cm)	172.77 $\pm$ 60.82	195.25 $\pm$ 58.82	0.009
Placental Volume (cu.cm)	270.8 $\pm$ 132	385.01 $\pm$ 142.66	0.001
Fetal birth Weight (gms)	2271.2 $\pm$ 788.04	2584 $\pm$ 682.35	0.003

**Table 3: Correlation of placental morphometry with fetal outcome.**

	Fetal Birth Weight	Appar
Placental Weight	0.841	0.668
Placental Surface Area	0.536	0.488
Placental Volume	0.574	0.435

observed in preeclamptic placentae (Figure 2). There is a corresponding reduction in the mean fetal birth weight in the preeclamptic group, which is statistically significant.

In this study, there is a highly significant positive correlation between placental morphometry and fetal outcome (Table 3), i.e. With a decrease in placental morphometric values, the fetal outcome will be adversely affected.

## DISCUSSION

Preeclampsia is usually defined as the development of hypertension and proteinuria after 20 weeks of gestation in a previously normotensive woman. It is also the 2nd major cause of maternal mortality worldwide and is reported to affect 5% to 7% of pregnant women worldwide [6,7]. Preeclampsia is considered to be a major contributor to the maternal and neonatal mortality and morbidity [8,9].

The etiopathogenesis of preeclampsia continues to be an area of extensive research, but it is believed that the cause is multifactorial. It forms a deadly triad together with hemorrhage and infection in the context of maternal morbidity and mortality. Also toxemia of pregnancy is well known for its association with fetal growth restriction and prematurity, thereby contributing to perinatal mortality and morbidity. However, it is acknowledged that it is the existence of the placenta rather than the fetus, which remains accountable for development of preeclampsia. Typically, the disease process ceases once the fetus and the placenta are delivered. In reality, when the placental bed is curetted immediately in the postpartum, the maternal blood pressure is brought down at a faster pace than when curettage is not done. The fact that preeclampsia arises even in the absence of the fetus, for e.g., in hydatidiform moles, proves that preeclampsia ultimately depends on the presence of placental tissue.

The gross lesions that are significant in preeclamptic placentae are : Infarction and Retro placental hematomas. The incidence of placental infarction ranges from about 33% in cases of mild preeclampsia

to approximately 60% in patients with severe form of the disease. Extensive infarction (involving more than 10% of parenchyma) is found in about 30% of placentae from cases of severe preeclampsia, but not a feature of the milder forms of this disease [10]. Infarction is the dramatic and easily recognized visible sign of maternal uteroplacental vascular insufficiency. Infarcts are more significant when they are central and greater than 3 cm in greatest dimensions. Infarction is associated with significant perinatal mortality and morbidity, including IUD, fetal hypoxia and neonatal mortality and morbidity. Extensive infarction occurs only against a background of markedly abnormal maternal vasculature and a restricted maternal blood flow to the placenta and it is these factors rather than the loss of villi due to infarction which are the real cause of the fetal complications. The true significance of extensive placental infarction is therefore that it is the visible hallmark of a severely compromised circulation to the placenta.

Retroplacental hematoma (RPH) are found unduly frequently in preeclamptic placenta, occurring in about 12-15% of all cases. There is a majority of opinion saying, this hemorrhage is a result of rupture of a maternal decidual arteriole, which is believed to be a catastrophe occurring in the vessel wall that has been weakened due to changes in preeclampsia [11-16]. Initially abruption was considered specific and integral part of preeclamptic process [17,18]. In support of this, in various reviews on abruption, there were a high percentage of patients affected by preeclampsia [19-22]. However in some reviews on abruption, the percentage of preeclamptic patients has been on a lower level [23,24]. Large lesions where in 40% or more of villous population is acutely deprived of blood supply are associated with high incidence of fetal hypoxia, death. Subamniotic hematoma, marginal hematoma, massive sub chorionic thrombosis intervillous thrombosis is of not much clinical significance. Placental calcification often regarded as evidence of either placental senescence or degeneration and of no pathological or clinical significance and not associated with any fetal complication.

## Histological findings

Villi of most preeclamptic placentas have normal maturity for that gestational period. However in a few cases, there is notable delay in villous maturation and it was found that this was by large restricted to severely preeclamptic pregnancies with resultant severe growth retarded fetus [25]. Still on the contrary some preeclamptic placenta showed evidence of accelerated villous maturation. The most characteristic and striking features of villi in preeclampsia are undue number as well as prominence of villous cytotrophoblastic cells and irregular thickening of trophoblastic basement membrane (TBM) (best appreciated when stained with PAS). The intensity of these changes correlates with duration and severity of maternal preeclampsia. Fetuses whose placenta contains a marked excess of villi with abnormally thick TBM have a much higher incidence of clinical hypoxia than do those in which the changes are absent. However, various

studies say that the high incidence of fetal hypoxia found in association with this abnormality is due, not to basement membrane changes, but to the ischemia which is responsible both for the histologic changes and fetal complications. The vascularization of the villi is often normal but a significant percentage of placental villi are hypovascular. They contain relatively inconspicuous, non-dilated, small vessels. This particular change correlates with the level of obliterative endarteritis of fetal stem arteries [26], which is found in around one third of preeclamptic placentae. These hypovascular villi which are inadequately perfused from fetal side show abundant syncytial knotting, lack vasculosyncytial membrane (VSM) and have increased amount of stromal collagen. The hypoxic placenta in preeclampsia is composed of numerous branched, short and fist like appearance of terminal villi. This greatly enhances the degree of syncytial knotting (flat sections), that a net like appearance may be discovered in the two dimensional picture.

Villous edema may also be found in placenta from women with preeclampsia. The cause of villous edema is unknown, it has been attributed to functional insufficiency of fetal circulation. Increased size of the edematous villi may decrease the capacity of intervillous space (IVS) and thus limit the maternal flow through the placenta. Fibrinoid degeneration of villi first appears as a small nodule of homogenous, acidophilic, PAS positive material at one point in the villous trophoblast. This nodule progressively enlarges as fresh fibrinoid material is laid down on its deep aspect so as to form a mass which gradually bulges into and compresses the villous stroma. This process continues until the whole villous is converted into a fibrinoid nodule. The incidence of villous fibrinoid necrosis is found to be moderately increased in preeclamptic placentas. The lesion has been attributed to an immunological reaction within villous tissue and to amyloid deposition as an ageing change.

#### Pathogenesis of morphologic changes

Most of the changes in preeclamptic placentae except are a consequence of abnormal maternal uteroplacental vasculature. This fact of reduced blood flow has been well established over many years [27-29] and confirmed with Doppler studies [30-33]. This uteroplacental insufficiency is a result of incomplete trophoblastic invasion of placental bed spiral arteries which are inadequately converted to uteroplacental vessels. The increase in incidence of placental infarction in preeclampsia is attributed to atherosclerosis in spiral arteries. Cytotrophoblastic hyperplasia is a specific response and TBM thickening a non-specific response to placental ischemia. Thus these are direct effects of reduced maternal blood flow. The excess of syncytial knots and villous stromal fibrosis are a result of reduced villous perfusion due to obliterative endarteritis of fetal stem vessels, which is a hallmark for prolonged vasoconstriction of these stem vessels. This leads to rise in placental vascular resistance [34]. All this represents the fetal hemodynamic response to uteroplacental

ischemia [35-37]. This reduction in placental fetal perfusion is in fact a compensatory mechanism by which there is preferential diversion of blood to the vital cerebral and cardiac circulation of fetus. Itskovitz et al considered that the villous tissue can enhance oxygen extraction in the face of decreased blood flow and can withstand a reduction of 50% blood flow without having any adverse effect on fetal oxygenation [38].

#### Fetus in pre eclampsia

Fetal growth restriction (FGR) is the end point of a number of pregnancy associated conditions and preeclampsia (PE) is one of them. PE is regarded as a syndrome of heterogeneous origin and fetal growth is very often restricted in it. Preeclampsia with shallow trophoblastic invasion of decidual arteries, reduce placental perfusion and cause insufficient transport of nutrients to fetus. Placental morphologic changes vary substantially in PE and it has been hypothesized that FGR depends on abnormal placental development. Pathophysiological process of FGR and the responses of fetus to the restricted nutrition and oxygen supply are very complex and far from fully understood. Odegard, et al. made a study and reported that PE was associated with a 5% reduction in birth weight. In severe PE, the reduction was 12% and in early onset disease, birth weight was 23% lower than expected. The risk of SGA was four times higher in infants born to women with PE among nullipara. PE associated with threefold higher risk of SGA and among parous, the risk of SGA was particularly high after recurrent PE. They concluded that factors like multiparity, severity of disease (mild, moderate and severe) and late versus early onset disease play a synergistic role in FGR in PE. Though the possibility that it represents an immune attack on trophoblastic tissue cannot be totally discarded and should be borne in mind [39].

In this study, it was observed that there is a negative correlation between severity of preeclampsia and the placental morphometric features like placental weight, volume and surface area (i.e.) with increasing severity of preeclampsia, there is a significant decrease in the placental weight, volume and surface area.

The incidence of retroplacental hematoma and infarction is significantly raised in the preeclamptic group with an increase in the mean no. of areas/lpf of syncytial knot formation, cytotrophoblastic cellular proliferation, villous fibrinoid degeneration, villous stromal fibrosis and irregular thickening of TBM compared to the control group. There is reduction of placental weight, mean placental volume and mean placental surface area in the preeclamptic group in comparison to the normal group. Fetal and placental growth restriction was frequently encountered manifestations of preeclampsia. The fetal weight is significantly reduced in the hypertensive group than in the control group, which corroborates with studies of other workers Damania (1989), Fox (1994), Kalousek (1994), Pradeep S Londhe (2011). [40-44] Rath in 1994 quoted that the intercotyledonous

vasculature is altered, ending in low birth weight of infants [45]. This study revealed a significant correlation between placental morphometry and fetal outcome in the preeclamptic group, ie. the placentae with decreased morphometric values produced fetuses with low birth weight and a considerable decrease in the APGAR score.

### CONCLUSION

This study greatly emphasizes the importance of placental morphometry and its correlation with fetal outcome. Currently, with the help of three dimensional ultrasonography and Virtual Organ Computer – Aided Analysis (VOCAL), the placental volume can be ascertained in utero and a correlation with the fetal growth can be obtained. We suggest that inclusion of in-utero measurement of placental volume in routine monitoring of fetal wellbeing in preeclamptic pregnancies will help in better management of at risk fetus.

### CONFLICT OF INTEREST

None.

### REFERENCES

- Robboy SJ. Robboy's pathology of the female reproductive tract. Elsevier Health Sciences; 2009.
- Larsen LG, Graem N. Morphological findings and valve of placental examination at fetal and perinatal autopsy. *APMIS* 1999; 107:337-345
- Driscoll SG. Placental examination in a clinical setting. *Arch Patho Lab Med* 1991; 115:668-671.
- Kaplan C. Placental pathology for nineties. *Pathol Annu* 1993; 28:15-72.
- Narasimha A, Vasudeva DS. Spectrum of changes in placenta in toxemia of pregnancy. *Indian J Pathol Microbiol* 2011; 54:15-20.
- Walker JJ. Inflammation and preeclampsia. *Pregnancy Hypertens* 2011; 1:43-47.
- Roberts JM, Cooper DW. Pathogenesis and genetics of preeclampsia. *Lancet* 2001; 357:53-56.
- Sibai BN, Caritis SN, Thom E, et al. Prevention of preeclampsia with low-dose aspirin in health. Nulliparous pregnant women. *N Engl J Med* 1993; 329:1213-1218.
- Levine RJ, Hauth JC, Curet LB, et al. Trial of calcium to prevent preeclampsia. *N Engl J Med* 1997; 337:69-76.
- Fox H. The significance of placental infarction in perinatal morbidity and mortality. *Neonatology* 1967; 11:87-105.
- Mckelvey JG. Vascular lesions in the deciduas basalis. *Am J Obstetr Gynaecol* 1939; 38:186-194.
- Sexton LI, Hertig AT, Reid DE, et al. Premature separation of the normally implanted placenta: A clinicopathological study of 476 cases. *Am J Obstetr Gynecol* 1950; 59:13-24.
- Van den Ende IE. The anatomy and pathology of premature separation of the placenta. *South African Med J* 1959; 33:737-740.
- Brosens I. A study of the spiral arteries of the decidua basalis in normotensive and hypertensive pregnancies. *Obstetr Gynecol Survey* 1964; 19:736-738.
- Marais WD. Human decidual spiral arterial studies-Part VIII. The aetiological relationship between toxemia-hypertension of pregnancy and spiral arterial placental pathology-A statistical study. *South African Med J* 1963; 37:117-120.
- Prathiba A. A comprehensive study of placental morphometry and histomorphology in normal and hypertensive pregnancies (Doctoral dissertation, Madras Medical College, Chennai).
- Bartholomew RA, Colvin ED, Grimes WH, et al. The mechanism of bleeding during pregnancy. *Am J Obstetr Gynaecol* 1953; 66:1042-1061.
- Fish JS. Hemorrhage of late pregnancy. Springfield 1955.
- Daro AF, Gollin HA, Nora EG, et al. Premature separation of the normally implanted placenta: A review of 306 cases. *Am J Obstetr Gynecol* 1956; 72:599-606.
- Barry AP, Feeney JK, Geoghegan FJ. Accidental haemorrhage. *Br Med J* 1955; 2:12.
- Vermelin H, Braye M. Pthogenie de themorrhagie retroplacentaire. *Gynecol Obstetr* 1958; 57:1-8.
- Oyelese Y, Ananth CV. Placental abruption. *Obstetr Gynecol* 2006; 108:1005-1016.
- Kimbrough RA. Antepartum hemorrhage: A review of 383 cases of abruptio placentae and 169 cases of placenta previa treated during the years 1944 to 1957. *Am J Obstetr Gynecol* 1959; 78:1161-1168.
- Hendelman M, Fraser WD. A clinical analysis of abruptio placentae. *Am J Obstetr Gynecol* 1960; 80:17-20.
- Teasdale F. Histomorphometry of the human placenta in maternal preeclampsia. *Am J Obstetr Gynecol* 1985; 152:25-31.
- Las Heras J, Haust MD, Harding PG. Morphology of fetal placental stem arteries in hypertensive disorders ('toxemia') of pregnancy. *Applied Pathol* 1983; 1:301-309.
- Browne JM. The uterine circulation in toxemia. *Clin Obstetr Gynecol* 1958; 1:341-347.
- Morris N, Osborn SB, Wright HP, et al. Effective uterine blood-flow during exercise in normal and pre-eclamptic pregnancies. *Obstetr Gynecol Survey* 1957; 12:23.
- Lunell NO, Nylund LE, Lewander R, et al. Uteroplacental blood flow in pre-eclampsia measurements with indium-113m and a computer-linked gamma camera. *Clin Exp Hypertension* 1982; 1:105-117.
- Campbell S, Griffin DR, Pearce JM, et al. New doppler technique for assessing uteroplacental blood flow. *Lancet* 1983; 321:675-677.

31. Cohen-Overbeek T, Pearce JM, Campbell S. The antenatal assessment of utero-placental and fetoplacental blood flow using Doppler ultrasound. *Ultrasound Med Biol* 1985; 11:329-339.
32. Arduini D, Rizzo G, Romanini C, et al. Utero-placental blood flow velocity waveforms as predictors of pregnancy-induced hypertension. *Eur J Obstetr Gynecol Reproductive Biol* 1987; 26:335-341.
33. Leiberman JR, Md IM, Md EM, et al. Unilateral and bilateral increase in resistance to blood flow in arcuate arteries during hypertensive disorders of pregnancy. *Clin Exp Hypertens* 1989; 8:603-611.
34. Trudinger BJ, Cook CM. Doppler umbilical and uterine flow waveforms in severe pregnancy hypertension. *Int J Obstetr Gynaecol* 1990; 97:142-148.
35. Stock MK, Anderson DF, Phernetton TM, et al. Vascular response of the fetal placenta to local occlusion of the maternal placental vasculature. *J Dev Physiol* 1980; 2:339-346.
36. Howard RB, Hosokawa T, Maguire MH. Hypoxia-induced fetoplacental vasoconstriction in perfused human placental cotyledons. *Am J Obstetr Gynecol* 1987; 157:1261-1266.
37. Jackson JA, Wailoo MP, Thompson JR, et al. Early physiological development of infants with intrauterine growth retardation. *Arch Dis Childhood Fetal Neonatal* Edn 2004; 89:46-50.
38. Itskovitz J, LaGamma EF, Rudolph AM. The effect of reducing umbilical blood flow on fetal oxygenation. *Am J Obstetr Gynecol* 1983; 145:813-818.
39. Odegard RA, Vatten VJ, Nilsen ST, et al. Preeclampsia and fetal growth. *Obstetr Gynaecol* 2000; 96:950-955.
40. Kalra VB, Aggarwal A, Sareen PM, et al. Histopathological changes in placenta in toxemia of pregnancy. *J Obstet Gynaecol India* 1985; 35:86-90.
41. Benirschke K, Kaufmann P. Pathology of the human placenta. 4<sup>th</sup> Edn. Springer Verlag 2000.
42. [https://link.springer.com/chapter/10.1007/978-1-4612-2548-5\\_1](https://link.springer.com/chapter/10.1007/978-1-4612-2548-5_1)
43. Mirro R, Brown DR. Edema, proteinuria, thrombocytopenia, and leucopenia in infants of preeclamptic mothers. *Ame J Obstetr Gynaecol* 1982; 144:851-852.
44. Schmidt BK, Muraji T, Zipursky A. Low antithrombin III in neonatal shock: DIC or non-specific protein depletion?. *Eur J Pediatr* 1986; 145:500-503.
45. Mayhew TM, Charnock-Jones DS, Kaufmann P. Aspects of human fetoplacental vasculogenesis and angiogenesis. III. Changes in complicated pregnancies. *Placenta* 2004; 25:127-139.