

# Histopathological Association with Abnormal Uterine Bleeding by Using Diagnostic Hysteroscopy

Neranjana D, Jayalakshmi G\*

Department of Microbiology, Sri Lakshmi Narayana Institute of Medical Sciences, Affiliated to Bharath Institute of Higher education and Research, Chennai, Tamilnadu, India

## ABSTRACT

The outcomes of hysteroscopy and curettage were in accord in 82 percent of the participants in this study. In 12% of cases, hysteroscopy showed more evidence than curettage, and curettage provided more detail than hysteroscopy in 6% of instances. A total of 50 individuals with Unusual Uterine Bleeding had a panoramic hysteroscopy and curettage procedure. When analyzing irregular uterine bleeding, today's modern gynecologist is concerned about missing a major malignant lesion. If we conform to the criteria for a poor hysteroscopy examination, the odds of missing such a lesion are slim, and no further examination is usually required. Even if the hysteroscopy view is negative, it is important to take endometrial samples for histological analysis, especially in peri or post-menopausal individuals.

**Key words:** Ultrasonography, Uterine bleeding; hysteroscopy, Endometrium

**HOW TO CITE THIS ARTICLE:** Neranjana D, Jayalakshmi G, Histopathological Association with Abnormal Uterine Bleeding by Using Diagnostic Hysteroscopy, J Res Med Dent Sci, 2022, 10 (6):245-247.

**Corresponding author:** Jayalakshmi G

**e-mail** ✉: jayalakshmi.2k15@gmail.com

**Received:** 16-May-2022, Manuscript No. JRMDs-22-66698

Editor assigned: 18-May-2022, **PreQC No.** JRMDs-22-66698 (PQ);

**Reviewed:** 02-June-2022, QC No. JRMDs-22-66698;

**Revised:** 07-June-2022, Manuscript No. JRMDs-22-66698 (R);

**Published:** 14-June-2022

## INTRODUCTION

Clinical management objectives are generally determined by obtaining an accurate etiological assessment. The history, physical examination, and thorough assessment are all used to try to figure out where the bleeding is coming from and what is causing it. The knowledge gained will help determine the path of the study. The most common studies used in the assessment of the etiology of abnormal uterine bleeding were classically dilatation and curettage and ultrasonography [1,2]. Because dilatation and curettage is a blinded treatment, the endometrium must be delivered to a scientist for histological analysis and a conclusion. The pathologist's participation is critical. Ultrasonography obviously indicates the uterine contour and ovarian status; however it does not provide enough knowledge on the endometrium. In the examination of abnormal uterine bleeding, hysteroscopy has brought a new age [3]. In the majority of situations, direct imaging of the uterine cavity can diagnose the aetiology. It is capable of detecting endometrial hyperplasia and assisting in the early identification of endometrial cancer and uterine

polyps [4].

One of the most prevalent problems that patients bring to a Gynecologist is abnormal uterine bleeding. D&C has traditionally been the standard method in the diagnosis of abnormal uterine bleeding. However, only about 70% to 80% of the endometrium can be cured. Curettage alone commonly fails to uncover polyps and submucous fibroids. The careful application of hysteroscopy to treat this medical condition adds another dimension to the treatment of this often perplexing issue. The goal of this review is to examine the role of hysteroscopy in the detection of Abnormal Uterine Bleeding in order to determine the accuracy of hysteroscopic observations and the procedure's impact to specific diagnosis. It also intends to link hysteroscopic findings to histological findings [5-7].

## MATERIALS AND METHODS

The data for this study came from individuals who were hospitalized to the Obstetrics and Gynecology department with abnormal uterine bleeding. Hysteroscopy and histological investigation were used to analyse the pattern of endometrium in 50 patients with AUB. All patients were given complete information about the trial and given formal informed consent. All of the study participants had hysteroscopy accompanied by curetting, with the curetting's forwarded to Histopathology for evaluation. The research took place from March 2020 to August 2021. Hysteroscopy and Endometrial Histopathology data were examined and

evaluated. The data was assessed and compared to comparable series in the research. A comprehensive chart has been prepared and presented that covers all topics. SPSS software was used for all statistical analysis.

**Inclusion-measures**

Patients age ranging 20 -60 years with uterine bleeding.

Both multi parous and nulliparous women were included.

**Exclusion-measures**

Profuse bleeding cases.

Cases of carcinoma cervix.

Patients on hormonal drugs.

The cases were chosen based on the diagnoses made during the history, comprehensive clinical assessment, abdominal and bimanual pelvic examinations, and routine procedures. The night before hysteroscopy, participants were recommended to have a light dinner before 10 p.m. The participants were prepared in the same way as they would be for any other surgical treatment.

**RESULTS AND DISCUSSION**

In this study, half of patients with Abnormal Uterine Bleeding had panoramic hysteroscopy with a 4mm hysteroscopic with a 30 degree oblique lens (Kalelkar, India) and were then treated with Curettage. Histopathological examination of the curetted endometrium was performed. The maximum age occurrence in this study was between 30-39, with 20 cases (40 percent). The study's youngest patient was 24, and the oldest was 60 (Table 1).

The most of the trauma patients had problems for more than a year: 21 (42%) had difficulties for more than a year, 15 (30%) had difficulties for 6 months to a year, and 14 (28%) had difficulties for less than 6 months. Menorrhagia was the most common symptom in 23 (46%) of the patients. Postmenopausal Bleeding was the second most prevalent group, with 16 instances (32 percent). Polymenorrhagia affected 6 individuals (12%), while Metrorrhagia affected 5 patients (10%) which are shown in Figure 1.

In 23 individuals (46%), aberrant results were found, whereas no abnormality was found in the remaining 27 patients (54%) (Negative hysteroscopic view). Thickened Endometrium (10 instances, 20%) was the most prevalent anomaly, followed by Endometrial Polyps (7 cases, 14 percent). There were also two cases of Submucous Myomas (4%), three cases of Endometrial

Atrophy (6%), and one case of Endometritis (2%). Histopathology revealed two aberrant findings: one case of endometrial atrophy and one case of endometritis. On hysteroscopy, one incidence of endometritis was later identified as normal (Figure 2).

In 50 consecutive instances of AUB, diagnostic hysteroscopy was done, and its association with histological results was explored. Menorrhagia (46%) was the most prevalent presenting ailment in this study, followed by Postmenopausal Bleeding (32%), and Polymenorrhagia (22%) (12 percent). Menorrhagia accounted for 60% of the cases in Panda's 33 series. In this study, aberrant results on hysteroscopy were discovered in 23 individuals (46%), whereas no abnormality was identified in the remaining 27 patients (54%). The test made a false positive diagnosis of endometritis in one case and missed the identification of endometrial atrophy and endometritis in one case [8-11]. In this study, hysteroscopy accuracy was 94 percent, while endometrial histopathology accuracy was 88 percent. A comparison of the accuracy of the product to that of other similar products (Table 2).

Statistical analysis of hysteroscopy accuracy and precision; The sensitivity and specificity acquired in this study and those obtained by many other authors are not significantly different. This supports the findings of the current study's hysteroscopy (Table 3) [12,13].

Hysteroscopy and dilatation and curettage findings were in accord in 82 percent of cases in the current study; hysteroscopy showed more data than curettage in 12 percent of cases, and curettage provided more

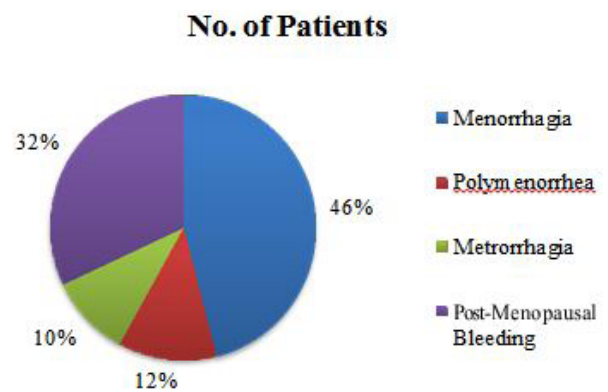


Figure 1: Clinical presentation.

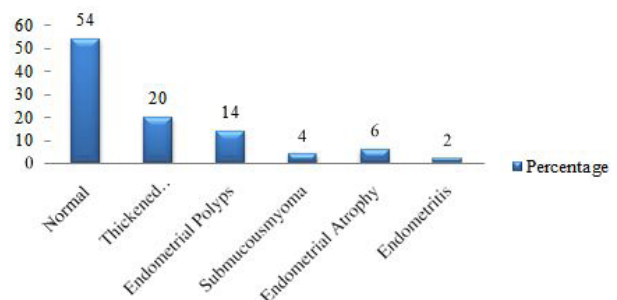


Figure 2: Findings at hysteroscopy.

Table 1: Age range in study.

Age range	Cases	Mean
20-29	2	4
30-39	20	40
40-49	18	36
50-60	10	20

Table 2: Identification after hysteroscopy and histopathology.

Identification	Menorrhagia	Polymenorrhoea	Metrorrhagia	PMB	Total	
					No.	%
Polyp	5	1	0	1	9	14
Fibroid	1	1	0	0	2	4
Hyperplasia	1	0	2	7	8	20
Endometritis	1	0	0	0	1	6
E. Atrophy	0	0	1	3	4	8
Normal	15	4	2	5	26	48
Total	23	6	5	16	50	100

Table 3: Accuracy of hysteroscopy diagnosis.

Reference	Accuracy	False positive
Baggish	87.5	12.5
Barbot	84	16
Sheth	82	18
Parasnis	92	8
Panda	92.69	7.31
Present Study	94	6

F Test p = 1 > 0.05 NS

Table 4: Comparison of validity factors curettage.

Author	Sensitivity	Specificity
Loverro	79.2	95
Garuti	78	94
Loffer	65	100
Parasnis	76	100
Present Study	79.16	96.15

knowledge than hysteroscopy in 6 percent of cases (Table 4). This study is consistent to others that have found that Panoramic Hysteroscopy is superior to curettage in detecting abnormal uterine haemorrhage.

### CONCLUSION

In examining individuals with uterine bleeding, hysteroscopy is preferable than curettage, according to this study. With high sensitivity, specificity, and negative predictive value, hysteroscopy is a safe, reliable, and rapid technique for diagnosing cases of irregular uterine bleeding. When analyzing irregular uterine bleeding, today's gynecologist is concerned about missing a major malignant tumour. If we conform to the criteria for a negative hysteroscopic examination, the odds of missing such a lesion are slim, and no additional study is typically required. Even if the hysteroscopic view is negative, it is important to take endometrial tissue for histological analysis, especially in peri or postmenopausal individuals.

### REFERENCES

1. Baggish MS. Operative Hysteroscopy. In: Rock JA, Jones

HW. TeLinde's operative gynecology 9<sup>th</sup> Ed. Philadelphia: Lippincott Williams Wilkins 2003; 379 -411.

2. Brundin J, Thomasson K. Cardiac gas embolism during carbon dioxide hysteroscopy: Risk and management. Eur Journal Obstetr Gynecol Reprod Biol 1989; 33:241-245.
3. Norment WB. A study of the uterine canal by direct observation and uterogram. Am J Surg 1943; 60:56.
4. Englund S, Ingelman-Sundberg A, Westin B. Hysteroscopy in diagnosis and treatment of uterine bleeding. Gynaecologia 1957; 143:217.
5. Menken FC. Endoscopic observations of endocrine processes and hormonal changes. In Simposio Esteroides Sexuales 1968; 24.
6. Barbot J, Parent B. Contact hysteroscopy: Another method of endoscopic examination of the uterine cavity. Am J Obstet Gynecol 1980; 136:721.
7. Valle RF. Hysteroscopic evaluation of patients with abnormal uterine bleeding. Surg Gynecol Obstet 1981; 153:521-526.
8. Loffer FD. Hysteroscopy with selective endometrial sampling compared with dilatation and curettage for abnormal uterine bleeding: The value of negative hysteroscopic view. Obstet Gynecol 1989; 73:16 -20.
9. Bain C, Park DE, Cooper KG. Is outpatient diagnostic hysteroscopy more useful than endometrial biopsy alone for investigation of abnormal uterine bleeding in unselected premenopausal women? A randomized comparison. Br J Obstet Gynecol 2002; 109:805-811.
10. Marleschki V. Contact hysteroscopy with the universal 4mm hysteroscope. In: Siegler AM, Lindemann HJ. Hysteroscopy: Principles and practice. Philadelphia: JB Lippincott 1984; 58 -62.
11. Siegler AM. Office hysteroscopy. Obstet Gynecol Clin North Am 1995; 22:457-471.
12. Chuong CJ, Brenner PF. Management of abnormal uterine bleeding. Am J Obstet Gynecol 1996; 175:787-792.
13. Munro MG, Critchley HO, Broder MS, et al. FIGO classification system (PALMCOEIN) for causes of abnormal uterine bleeding in nonpregnant women of reproductive age. Int J Gynaecol Obstet 2011; 113:3-13.