

Modification of Prudhomme's Classification of Retro-Duodenal Bilio-Arterial Relations and Their Significance in the Operative Management of Hemorrhagic Duodenal Ulcer-An Anatomosurgical Study

Nasser A. N. Alzerwi

Department of Surgery, College of Medicine, Majmaah University, Ministry of Education, Al-Majmaah City,
11952, P. O. Box 66, Riyadh Region, Kingdom of Saudi Arabia

ABSTRACT

Background: The modern lifestyle and stress have been known to impact on everyday life. The duodenal ulcers are one such example and are a direct result of the above-mentioned influences. This condition can be due to infectious or non-infectious origin. Duodenal Anatomy is quite complex, and all credit goes to its embryological origin. Duodenal ulcers are quiet commonly encountered in the clinical and surgical practice. Hemorrhagic ulcers are one complication of the posteriorly penetrating duodenal ulcers. Treating a hemorrhagic ulcer is challenging as there are a number of ways, which has been described and many of which are actually followed in the standard surgical treatment which might endanger the common bile duct during ligation of the gastroduodenal artery. Knowing the relationship between the common bile duct and gastroduodenal artery is very important in the surgical management of the duodenal ulcers. This study puts in an effort for the same.

Methods: This study is intended to be of great help to the practicing surgeons. The cadavers were selected and dissected, from July 1st, 2018 to December 31st, 2019, Department of Anatomy, JNUIMSRC. Duodenal morphometry, Origin of the gastroduodenal artery, mean distance between gastroduodenal artery and pylorus, relationship of gastroduodenal artery with bile duct in a transverse plane, Presence of pancreatic tissue between the gastroduodenal artery and bile duct was also observed. And findings were compared with Prudhomme's classification for validation and modification.

Result: Common bile duct is always posterior in position when compared to gastroduodenal artery. And in majority of the cases they will diverge from one another. The presence of pancreatic tissue was found in all cases. Two new variants were found, and the original Prudhomme's classification was modified accordingly.

Conclusion: Variant III and IV are the most vulnerable variation for inadvertent injury to the common bile duct during deep blind ligation of the gastroduodenal artery for a hemorrhagic penetrating bulbar duodenal ulcer. The relations of these two important structures to the 1st part of duodenum is especially important and should be known to the practicing surgeons as prompt diagnosis and treatment will be the need of the hour in such emergencies.

Key words: Relationship, Common bile duct, Gastroduodenal artery, Cross sectional, Descriptive, Cadaveric

HOW TO CITE THIS ARTICLE: Nasser Alzerwi, Modification of Prudhomme's Classification of Retro-Duodenal Bilio-Arterial Relations and Their Significance in the Operative Management of Hemorrhagic Duodenal Ulcer-An Anatomosurgical Study, J Res Med Dent Sci, 2020, 8 (4):110-117.

Corresponding author: Nasser Alzerwi

e-mail ✉: n.alzerwi@mu.edu.sa

Received: 01/07/2020

Accepted: 20/07/2020

INTRODUCTION

Duodenal ulcers are quiet commonly encountered in the clinical and surgical practice [1]. Treating a hemorrhagic ulcer is challenging as there are a number of ways, which has been

described and many of which are actually followed in the standard surgical treatment, that might inadvertently injure the common bile duct during deep blind ligation of the gastroduodenal artery [2]. The Duodenum is a retroperitoneal organ except for first 2-3cm. It is C-shaped and curving around head of pancreas. First part of duodenum is around 50 mm in length. It traverses right arising from the pyloric part of the gastric antrum and meets the 2nd part of the duodenum at a flexure. The first part of the

duodenum is related to the liver and the gall bladder anteriorly. Posteriorly the first part of the duodenum is related to the gastroduodenal artery which is in turn a branch of common hepatic artery in majority of the cases. The other important structures that are related to the first part of duodenum posteriorly are the bile duct and the portal vein. The bile duct along with the pancreatic duct opens in the posterior wall of the duodenum. The opening is called as the major duodenal papilla and the structure is protected by a fold of mucosa called as the plica. This opening in a majority of articles and textbooks has been quoted to be about ten centimeters from the pylorus. The opening is also important from an embryological point of view. That is, it is the point at which the foregut meets the midgut. In other words, the opening of the duct marks the point of junction between the foregut and the midgut. Actually, the liver and pancreas develop from the hepatic and pancreatic bud from these points [3]. So, it is wonderful to imagine these parts upside down when embryology of these parts is concerned.

Physiologically the first part of the duodenum is very important because the chyme that enters from the stomach is rich in acidic content, in fact the chyme is mixed thoroughly by the hydrochloric acid which is secreted by the parietal cells of the stomach. This acid in fact helps in conversion of the pro enzyme that is secreted by the chief cells i.e., the pepsinogen conversion to the active enzyme pepsin. Thus, the auto catalytic action takes place. The other important thing is that the parietal cells also secrete bicarbonate to neutralize this acid. These cells are less in number in the duodenum which makes the first part of the duodenum vulnerable to the acid ulcerogenic insult. The second part is protected by bile secretion [4]. Duodenal ulcers are more common in the 3rd to 5th decade of life and is more common in males. The classic symptom of pain after having food (post-prandial) is a well-known fact. [1]. The duodenal bulb of first part is the most commonly affected by duodenal ulcers. The most commonly encountered parts are the anterior and the posterior part. Stress and cigarette smoking are also known causes that precipitate this situation [2]. The signs and symptoms range from simple bloating or feeling fullness to life threatening complications like perforations

and hemorrhage [3]. The erect chest X-ray film which is commonly used to diagnose the acute abdomen cases may or may not help as free air in the peritoneum can be missed in approximately half of cases [5]. The gold standard is the GI endoscopy as it may be used both as a diagnostic and therapeutic modality [3]. H. Pylori infections are also quite common cause of duodenal ulcers.

Antibiotic regimes combined with proton inhibitors or antacids can be used for the medical management of this condition [2]. Sometimes penetration into the posterior wall cause profuse bleeding due to erosion into the gastroduodenal artery that is related posteriorly to the first part of the duodenum [6]. This can present as hematemesis (vomiting of blood) or it can pass in stool (melena). In around 20-25% of duodenal ulcer cases there are chances of hemorrhage [7]. The most preferred surgical option for hemorrhagic penetrating duodenal bulbar ulcer that's refractory to nonoperative medical treatment (Intravenous fluid resuscitation, Blood transfusion and endoscopic hemostatic measures) and associated with hemodynamic instability, is duodenotomy and transluminal deep blind hemostatic U-stitch [8, 9].

Gastroduodenal artery origins most commonly from Common Hepatic artery, which is again a branch of Celiac trunk. Vertebral level of origin of celiac trunk is T12 vertebra. According to a study it may also arise from the following in the following percentages, Left hepatic artery (4-11%) or right hepatic artery (7%) or Superior mesenteric artery via a replaced hepatic trunk (4-11%) [10]. This artery along with its branches gives arterial supply to stomach, duodenum and pancreas [1]. GDA hemorrhage is a leading cause of mortality and morbidity in case of duodenal ulcer as it is closely related to first part of duodenum, common bile duct and head of pancreas making it susceptible to injury during course of disease and surgery [3, 11]. Severe bleeding, perforation, and obstruction caused by duodenal ulcers are managed surgically. Complications of duodenal surgery may include bleeding, anastomotic leak or stricture, bile duct injury [12]. Primary objective of treatment plan of complicated duodenal ulcer is arrest of hemorrhage and eradication of ulcer [10]. Knowledge of anatomy of variant of gastroduodenal

artery and its relation with bile duct is vital for surgeons and gastroenterologists [13]. Prudhomme et al studied the anatomical relations of retroduodenal common bile duct and gastroduodenal artery and found four distinct patterns [7]. Knowing the relationship of common bile duct with gastroduodenal artery is very important as far as the surgical management of the duodenal ulcers is concerned to avoid inadvertent injury to CBD during the “blind” transluminal surgical ligation of the GDA in emergency life threatening hemorrhage from a penetrating bulbar duodenal ulcer. This study investigates the validity of Prudhomme classification and the need for modifying it.

METHODOLOGY

Study design: Observational cross-sectional study.

Study setting: Department of Anatomy, Kanachur Institute of Medical Sciences, Mangalore.

Study population: Embalmed cadavers from Kanachur Institute of Medical Sciences, Mangalore.

Sample size: 30 embalmed cadavers selected for dissection.

Study tool: Embalmed cadavers, standard flexible measuring tape marked to tenths of a centimeter.

Duration of the study: 18 months.

Sampling technique: Convenience sampling.

Data collection: After the dissection the Duodenal morphometry, Origin of the gastroduodenal artery, Mean distance between gastroduodenal artery and pylorus, relationship of gastroduodenal artery with bile duct in a transverse plane, Presence of pancreatic tissue between the gastroduodenal artery and bile duct was also observed. data collection was done and analyzed using SPSS version 23.

Data analysis: Descriptive statistics.

Ethical considerations: Ethical clearance was obtained from King Fahad Medical City.

Institutional review board IRB log number: 20-293E.

Materials and methods

The study was conducted at Department of Anatomy, Kanachur Institute of Medical Sciences, Mangalore, India. Thirty embalmed cadavers were dissected. Midline incision and transverse incision was taken, and then anterior abdominal wall was retracted into 4 parts. The porta hepatis was identified and the bile duct was identified. Then the duodenum was identified. Careful dissection was done to identify the gastroduodenal artery. Then duodenal morphometry was taken, origin of the gastroduodenal artery was traced, Mean distance between gastroduodenal artery and pylorus was taken, relationship of gastroduodenal artery with bile duct in a transverse plane was checked and noted, presence of pancreatic tissue between the gastroduodenal artery and bile duct was also observed. Findings were compared to Prudhomme classification [7] and any differences were added as a modification of that classification.

Prudhomme Classification: Prudhomme et al. [8] described his classification as follows:

Type 1: the tow structures separated progressively with the artery on the left side of the bile duct.

Type 2: the tow structures approached each other without crossing

Type 3: the GDA crossed in front of the bile duct at the level of D1.

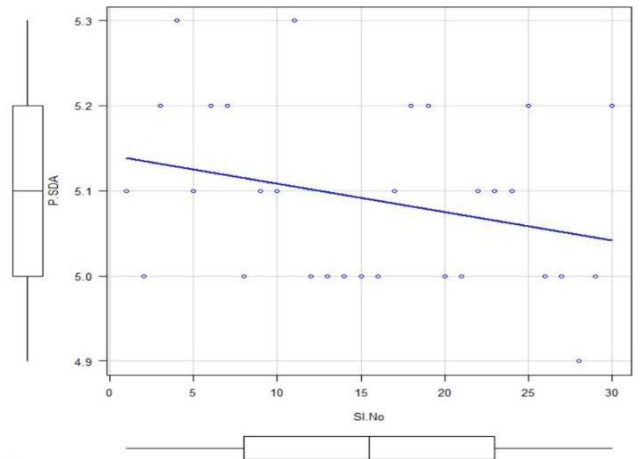
Type 4: the GDA crossed the bile duct below D1 and ran along its right side.

RESULTS

The mean length of between the pylorus and the superior duodenal angle was found to be 5.09 cms (Table 1 and Graph 1). The mean length of the Proximal segment (bulb) was found to

Table 1: Mean length from pylorus to the superior duodenal angle, and mean length of Proximal segment (bulb) and Distal retroperitoneal segment.

Mean length from pylorus to the superior duodenal angle	
Length	5.09 cm
Proximal segment (bulb)	3.41 cm
Distal retroperitoneal segment	1.5 cm



Graph 1: Mean length from pylorus to the superior duodenal angle.

Table 2: Mean distance between gastroduodenal artery and pylorus.

Distance	
Mean distance between gastroduodenal artery and pylorus	2.98 cm

be 3.41 cms and the mean length of the distal retroperitoneal segment was found to be 1.5 cms.

In all the 30 cases the gastroduodenal artery originated from the common hepatic artery.

The mean distance between gastroduodenal artery and pylorus was found to be 2.98 cms (Table 2).

There were four types of relation between gastroduodenal artery and common bile duct that was encountered.

Zerwi modification of prudhomme classification

Left (Figure 1a): Type 1: Zerwi I Sinistrally descending divergent GDA (Left lying GDA, note: Sinistral=Left): Where they diverge from each other, but the GDA stays to the left of CBD consistent with type 1 Prudhomme.

Right (Figure 1b): Type 2: Zerwi II Sinistrally descending convergent GDA (Left lying GDA, note: Sinistrally=Left) Where they go along and GDA stays left to the CBD, consistent with type 2 Prudhomme.

Left (Figure 2a): Type 3: Zerwi III Late Incompletely crossing anteriorly descending GDA, which is different from type 3 Prudhomme where the CBD crosses completely the CBD anteriorly and to the right of CBD and continues transversely and obliquely rather than descending vertically in front of the CBD. This

puts the CBD at higher risk of inadvertent injury during GDA blind ligation than Prudhomme type 3.

Right (Figure 2b): Type 4: Zerwi IV Early Completely crossing Dextrally descending GDA (Note: Dextral=right), partially consistent with prudhomme type 4, as the GDA in this study crossed the cbd early on, at the mid-level of duodenal bulb, not below D1 as in prudhomme type 4. This puts the CBD at a higher risk of inadvertent injury during deep blind ligation of GDA than Prudhomme type 4.

Figure 3 Shows the pointer pointed towards the bile duct and the gastroduodenal artery can be seen above the pancreatic tissue. So it's Zerwi III Incompletely Crossing Anteriorly Descending GDA.

Illustartion I shows the chances of injuring bile duct in Gastroduodenal ligation procedure (deep stitches) is highest for Zerwi III Incompletely Crossing Anteriorly Descending GDA.

Illustartion II shows the chances of injuring bile duct in gastroduodenal ligation procedure (deep stitches) is higher for Zerwi IV“ Early” completely crossing dextrally descending GDA, than for prudhomme type 4.

Table 3 shows the Frequency of types encountered based on the relation between gastroduodenal artery and common bile duct.

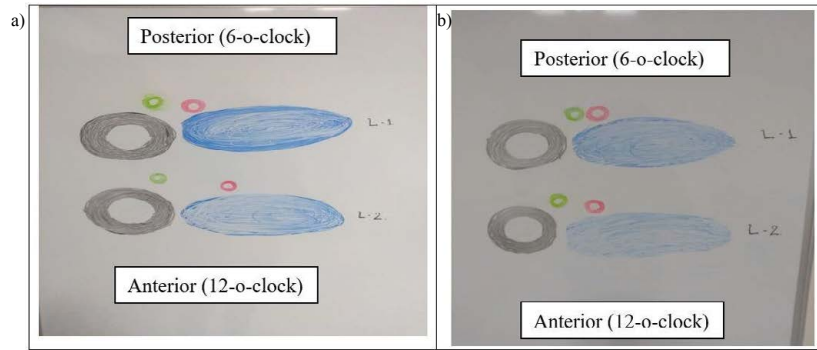


Figure 1: Cross sectional anatomy.

Note: (As seen from cephalad to caudad in a prone position).

L1: At the upper border of the duodenal bulb. L2: At the lower border of the duodenal bulb. Illustration to understand the relation between the duct and the artery.

Grey coloured structure: Duodenum.

Blue coloured structure: Pancreas.

Red coloured structure: Gastro - duodenal artery.

Green coloured structure: The common bile duct.

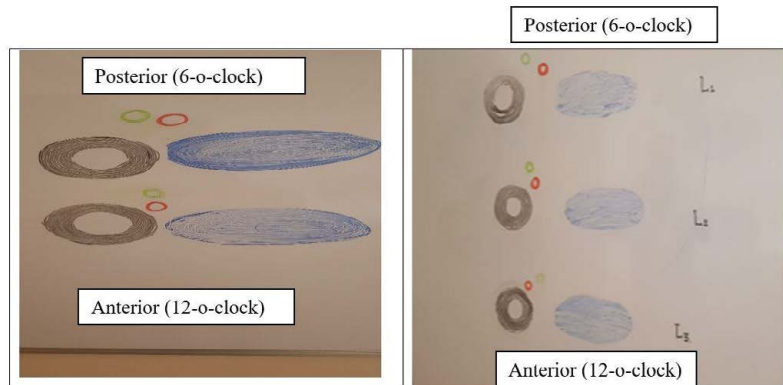


Figure 2: (A) Structures crosses one another and (B) artery passes on the right of the duct.

Note: (As seen from cephalad to caudad in a prone position).

2A-L1: At the upper border of duodenal bulb. L2: At the lower border of duodenal bulb. Illustration to understand the relation between the duct and the artery.

2B-L1: at the upper border of duodenal bulb.

2B-L2: through the middle section of duodenal bulb.

2B-L3: at the lower border of duodenal bulb.

Grey colored structure: Duodenum.

Blue colored structure: Pancreas.

Red colored structure: Gastro - duodenal artery.

Green colored structure: The cystic duct.

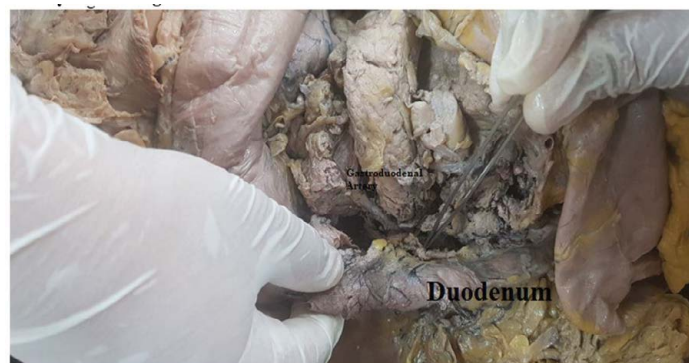

Figure 3: Showing the pointer pointed towards the bile duct and the gastroduodenal artery can be seen above the pancreatic tissue. So it's Zerwi III Incompletely Crossing Anteriorly Descending GDA.

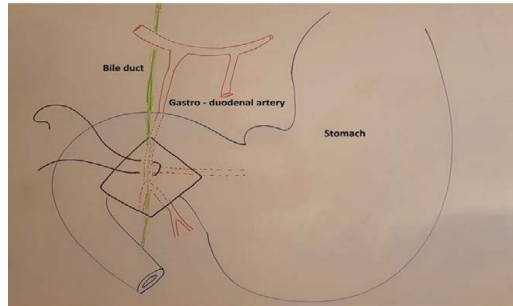


Illustration I: Chances of injuring bile duct in Gastroduodenal artery ligation procedure (deep stitches) is highest for Zerwi III Incompletely Crossing Anteriorly Descending GDA.

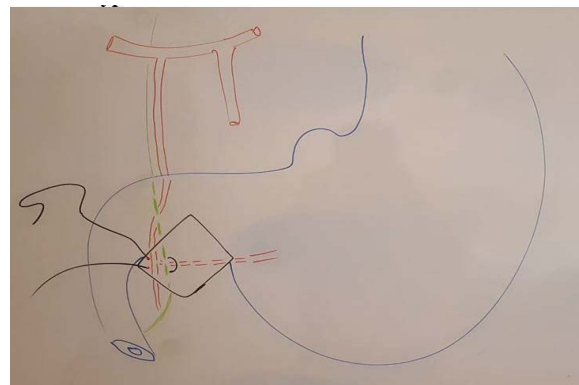


Illustration II: chances of injuring bile duct in gastroduodenal ligation procedure (deep stitches) is higher for Zerwi IV“ Early” completely crossing dextrally descending GDA, than for prudhomme type 4.

Table 3: Frequency of types encountered based on the relation between gastroduodenal artery and common bile duct.

Type	Frequency	Percentage
1	17	56.70%
2	9	30.00%
3	2	6.70%
4	2	6.70%

DISCUSSION

From outside inwards the duodenum is made up of the serous coat which is a part of visceral peritoneum. Then the muscularis externa which is contributed from the splanchnic mesoderm. This is a part of the lateral plate mesoderm. Then the submucosa, also develops from the same. The mucosal layer develops from the midgut. The mucosa develops from the endoderm. The opening of the bile duct into the 2nd part of the duodenum actually marks the junction of the fore gut with the midgut. Actually, development of mucous membrane of the duodenum above and including ampulla of Vater takes place from endoderm of foregut and rest from the midgut [12]. The total length of the duodenum is around 25 centimetres and is divided into 4 parts [14]. The first part and the second part which includes the ampulla of Vater develops from the foregut and is supplied by the coeliac trunk and its branches. This part is actually supplied by the

gastroduodenal artery and other branches of the coeliac trunk. The other parts below the ampulla is supplied by the branches of the superior mesenteric artery as it develops from the midgut [12]. The duodenum is the shortest and widest part of small intestine. Only the proximal 2.5 cm is intraperitoneal and remaining is retroperitoneal [14]. This happens because the anterior loop which is formed in embryogenesis makes a right angled ninety degree turn to the right, a courtesy of the rotation of the stomach and the liver which is the main culprit [7]. After this there is a process in which the peritoneum actually disappears or literally stitches the duodenum to the posterior abdomen wall through a process called zygosis. This rotation makes the gastroduodenal artery and the common bile duct come posteriorly to the first part of the duodenum [15].

Thus, first part of duodenum lies anterior to the gastroduodenal artery and common bile duct. The other structures encountered in here are

the portal vein and a small part of the pancreas. Gastroduodenal artery lies immediately behind the posterior wall of duodenum [11]. Gastroduodenal artery usually arises at the distance of 1.5 to 3 cm (range) above the first part of duodenum, and at a distance of 0.5 to 5 cm (range) from the pylorus. Arterial supply of duodenum consists of gastroduodenal, superior pancreaticoduodenal, inferior pancreaticoduodenal artery [6]. First part of duodenum is more prone to peptic ulcers [6]. The first part of duodenum is supplied by end arteries, which are supra-duodenal and retro-duodenal, branches of gastro-duodenal artery. One of the causes of erosion of gastroduodenal artery is presence of peptic ulcer in posterior wall of the duodenum. This artery arises from common hepatic artery and descends posteriorly to the 1st part of duodenum to the left of common bile duct or it can arise from coeliac axis or right or left hepatic artery. Two parts of the artery can be identified between the pancreas in the lesser omentum and secondly in between the pancreas and the duodenum. Pancreatic tissue separates it from posterior surface of duodenum. These parts are also termed as intra-epiploic and supra-pancreatic and second as inter- duodeno-pancreatic respectively. The common bile duct presents different kinds of relationships with the GD artery [7].

There is variable relationship between Common bile duct and Gastroduodenal artery [6, 7, 16]. Prudhomme classification of these relations has been validated before [17], however this is the first study to modify it. This study results are in agreement with Prudhomme's study in that the most common variants described in Prudhomme's classification (type 1 and 2) (Figure Ia, and Ib) are also the least prone to accidental injury during deep blind GDA ligation for a hemorrhagic penetrating bulbar duodenal ulcer, however, the Prudhomme type 3 was not replicated in our study, which might be due to the small sample size in both studies. This study, however, found a new variant (figure IIa) where the GDA crosses the CBD later in its course at lower border of the duodenal bulb, and descends anterior to the CBD vertically, rather than crossing completely and obliquely to the right of the CBD as described by Prudhomme above D1, making this variant riskier, as the CBD is more prone to injury, as the crossing

occurs behind the duodenal bulb compared to Prudhomme type 3 where the crossing occur above D1 and continues obliquely, making it vulnerable especially when the surgeon take the lower part of the U-stitch that's usually made to control the transverse pancreatic branch of the GDA which is the most common reason for technical failure and early recurrence of rebleeding (Illustration I) [7, 9], another variant which was different from Prudhomme's was type 4, where in this new variant (Figure IIb), the GDA crosses the CBD completely and continues descending vertically to the right of the CBD as in classical Prudhomme's type 4, however, it does so earlier in its course, at the mid-level border of duodenal bulb, rather than below D1 as described by Prudhomme's, making it especially vulnerable to inadvertent injury during GDA ligation, as surgeons usually choose the mid-level of duodenal bulb for a U-stitch (Illustration II) [8, 9]. A small pancreatic tissue separates the common bile duct from the posterior surface of distal part of duodenum retroperitoneally, which is also known as Duodenal tubercle or Omental tubercle of Wiart [6]. Presence of this "inter-cholecho-duodenal glandular" pancreatic tissue forms a protective curtain over it [6]. There are other variations that has been reported [7, 17], such as absence of pancreatic tissue between the CBD and GDA, however, this finding was not replicated in our study. The most important thing that an operating surgeon should remember is these variations. Otherwise catastrophe can occur as the misplaced hemostatic stitch may accidentally catch other vital structures, most commonly bile duct, though to the best of our knowledge, no such a complication has been reported yet, however, there might be a publication bias, as negative outcomes are less likely to be reported. A pancreatic tissue is usually considered safe in between structures but what if injury of the pancreatic tissue is caused?, this may cause autolysis of the first part of the duodenum and also close by structures and may cause greater harm than good to the patient. However, this variety which was not encountered in our study i.e., that there is no pancreatic tissue which covers the artery and the duct, may be a blessing to the operating surgeon as it is easy to handle [7, 17]. But as discussed earlier it is important to understand and know the relations of the gastroduodenal artery and the bile duct. This study clearly sheds

a light in understanding the different relations of the bile duct and the gastroduodenal artery. This study also successfully shows the origin of the gastroduodenal artery in relation to the pylorus and sheds effectively a light on the morphometry of the first part of the duodenum to be very helpful to the operating surgeon.

CONCLUSION

Out of the four varieties described by Prudhomme et al [7], only type 1 and 2 were found, in our study 2 new variants were found: Zerwi III and Zerwi IV which puts the GDA at a higher risk of inadvertent injury during blind deep ligation of GDA for hemorrhagic penetrating bulbar duodenal ulcer, than the classical Prudhomme type 3 and 4, respectively. There have been reports where the authors have reported some pancreatic tissue between the common bile duct and the gastroduodenal artery. This variety was not observed in our study. The relations are especially important, and this knowledge is very important to practicing general and hepatobiliary surgeons. This study was intended for a practicing surgeon to understand the retro - duodenal relations so as to avoid a potential serious surgical misadventure and the study has formulated a modification of the original Prudhomme four-type classification of these relations. Replication and validation studies are required.

LIMITATIONS

This study was conducted in thirty cadavers. This must be repeated in a larger sample in a multicentric, national and international setting, so as to come at a final conclusion.

Future Prospective of this research: Operative surgical anatomical dissection during pancreaticoduodenectomy procedures to validate this classification. Linear regression model after many such reports are available from multiple national and international centers, to be generalizable.

FUNDING

Self-funded by the author.

CONFLICT OF INTEREST

None.

ACKNOWLEDGEMENT

The author would like to thank Dr. Shishirkumar and Dr. Rati Tandon, from JNUIMSRC, Manglore,

India, for their help in dissecting the cadavers and collecting the data.

REFERENCES

1. <https://www.sciencedirect.com/topics/veterinary-science-and-veterinary-medicine/gastroduodenal-artery>
2. Prabhu V, Shivani A. An overview of history, pathogenesis and treatment of perforated peptic ulcer disease with evaluation of prognostic scoring in adults. *Ann Med Heath Sci Res* 2014; 4:22-29.
3. Kavitt RT, Lipowska AM, Yeboa AA, et al. Diagnosis and treatment of peptic ulcer disease. *Am J Med* 2019; 132:447-456.
4. Guyton and Hall textbook of medical physiology (Ebook, A South Asian Edition); *Exocrine pancreas* 2016; 437-439.
5. Gans SL, Stoker J, Boermeester MA. Plain abdominal radiography in acute abdominal pain; past, present, and future. *Int J Gen Med* 2012; 5:525.
6. Bonnel F, Pujol J, Barthélémy M, et al. Topographical relationships of the first part of the duodenum, gastroduodenal artery and bile duct. *Anat Clin* 1982; 4:289-294.
7. Prudhomme M, Canovas F, Godlewski G, et al. The relationships of the bile duct and the retroduodenal arteries and their importance in the surgical treatment of hemorrhagic duodenal ulcer. *Surg Radiol Anat* 1997; 19:227-230.
8. Van Lanschot JJB, Van Leerdam M, Van Delden OM, et al. Management of bleeding gastroduodenal ulcers. *Digestive Surg* 2002; 19:99-104.
9. Berne CJ, Rosoff L. Peptic ulcer perforation of the gastroduodenal artery complex: Clinical features and operative control. *Annals Surg* 1969; 169:141.
10. <https://epos.myesr.org/poster/esr/ecr2010/C-2049>
11. Desai GS, Pande PM. Gastroduodenal artery: Single key for many locks. *J Hepatobiliary Pancreat Sci* 2019; 26:281-91.
12. <https://oxfordmedicine.com/view/10.1093/med/9780190650506.001.0001/med-9780190650506>
13. Kapoor VK. What is in a name? Gastro duodenal artery or gastro-duodeno-pancreatic trunk. *Anat Physiol* 2017; 4:270.
14. Standring S. *Grays anatomy: The anatomical basis of clinical practice, small intestine*. Elsevier 2016; 41:1124-1129.
15. Dutta AK. *Essentials of human anatomy, thorax, abdomen and pelvis*. 2013; 242-246.
16. Kapoor VK. *Surgical anatomy of the hepato-biliary system. Post Cholecystectomy Bile Duct Injury*. Springer 2020; 1-10.
17. Chen JY, Shyu JF, Uen YH, et al. Surgical anatomy of the gastroduodenal artery in Chinese adults and its clinical applications. *Hepato-gastroenterology* 2007; 54:1458-1461.