

Retrospective Analysis of Causative Factor for Tooth Discoloration among Male Patients in Indian Population

Tasleem Abitha S, Subash Sharma*

Department of Conservative Dentistry and Endodontics, Saveetha Dental College & Hospital, Saveetha Institute of Medical and Technical Sciences, Saveetha University, Chennai, India

ABSTRACT

Introduction: A smile has been said to be among man's most important interactive communication skills. The public's importance for white teeth has driven dentists to strive to meet their patient's expectations of dental aesthetics. The appearance of the dentition is of concern to a large number of people seeking dental treatment and the colour of the teeth is of particular cosmetic importance.

Materials and methods: This study is a retrospective cross sectional study conducted in a Private Dental Institution, in Chennai to determine the causative factor of tooth discoloration with the approval from the Institutional Review Board. It included demographic data of the patients along with dental status of each individual. The data collection was done by reviewing the patient's record and analysed the data of June 2019 and March 2021.

Results: From our current study it is seen that around 50.9% of the participants were between the age group of 18-30 years. From the findings of the current study it is seen that, around 79.2% of the patients have undergone treatment for discoloration in relation to sextant 2 which is maxillary anterior.

Conclusion: Tooth Staining has several etiologic factors ranging from simple enamel hypoplasia to severe dental fluorosis. Many colour changes can be encountered when dealing with tooth discoloration. An understanding of the disease process is essential in determining the appropriate treatment modalities.

Key words: Dental stains, Discolouration, Fluorosis, Aesthetics

HOW TO CITE THIS ARTICLE: Tasleem Abitha S, Subash Sharma, Retrospective Analysis of Causative Factor for Tooth Discoloration among Male Patients in Indian Population, J Res Med Dent Sci, 2022, 10 (7):181-185.

Corresponding author: Subash Sharma

e-mail ✉: subash@saveetha.com

Received: 08-June-2022, Manuscript No. JRMDS-22-69299;

Editor assigned: 10-June-2022, **PreQC No.** JRMDS-22-69299 (PQ);

Reviewed: 24-June-2022, QC No. JRMDS-22-69299;

Revised: 29-June-2022, Manuscript No. JRMDS-22-69299 (R);

Published: 06-July-2022

INTRODUCTION

A smile has been said to be among man's most important interactive communication skills. The public's importance for white teeth has driven dentists to strive to meet their patients expectations of dental aesthetics 1. The appearance of the dentition is of concern to a large number of people seeking dental treatment and the colour of the teeth is of particular cosmetic importance [1,2].

There has been a recent increase in interest in the treatment of tooth staining and discolouration as shown by the large number of tooth whitening agents appearing on the market [3]. Discoloration being the prime cause of

esthetic dental treatment, etiology should be known to the clinician. There are numerous factors that result in tooth discoloration. Tooth discoloration can occur as a result of intrinsic or extrinsic factors. Also, it occurs as a result of surface stains due to actual changes in our tooth material, or because of a combination of both factors. Dental professionals have identified different categories of tooth discoloration [4].

Extrinsic discolouration

It is caused by agents resulting in staining of enamel or causing some kind of damage to the enamel. The involvement of the outermost layer of the tooth is usually seen which can be prevented by simple oral prophylaxis. Yellowish brown to black discoloration primarily on the lingual surfaces of the tooth involving the cervical portion is caused by cigarettes, cigars and pipes 5. Stains penetrating the deep enamel are caused by tobacco chewing. Brown to black tenacious discoloration is seen with the use of frequent intake of tea and coffee [5,6].

Intrinsic discolouration

The deposition and incorporation of substances within

enamel and dentin causes this kind of staining, for instance, tetracycline stains, stains in dentin genesis imperfect, fluorosis, jaundice (greenish discoloration due to bilirubin), dental trauma (gray or blue gray discoloration due to the breakdown of haemoglobin), dental materials used in restorative dentistry and medicines [7]. Long standing non vital tooth and periapical pathology also contribute to intrinsic staining [8].

Tetracycline staining

Tetracycline staining was first reported in mid-1950s, less than a decade after widespread use of this antibiotic. Teeth are most susceptible to tetracycline discoloration during their formation (i.e. 2nd trimester to 8 year after birth) due to tetracycline chelate formation with calcium and its incorporation into hydroxyapatite crystals [9]. It predominantly involves dentin and its severity depends on time, duration and dosage of the administration of tetracycline. Different forms of tetracycline cause different kinds of tooth discoloration [9,10]. There are various types of treatment available for teeth discoloration which includes removal of surface stains, micro abrasions, macro abrasions, veneering, placement of porcelain crowns and bleaching [11].

The psychological and social impact of tooth staining on patients has been greatly reported. Tooth staining may be the result of different etiological factors, it may have different appearances, location and severity [11,12]. Our team has extensive knowledge and research experience that has translated into high quality publications [13-32].

Hence, the aim of this study is to analyze the rationale and causative factor to tooth discoloration among male patients in the Indian population.

MATERIALS AND METHODS

This study is a retrospective cross sectional study

conducted in a Private Dental Institution, in Chennai to determine the class I vs. class II dental caries with the approval from the Institutional Review Board.

Data collection

Data is extracted from Patient management software of Saveetha dental college from the time period February 2020 to February 2021 based on the following inclusion and exclusion criteria's.

Inclusion criteria

- ✓ Patients who had fluorosis.
- ✓ Patients with discolored tooth.

Exclusion criteria

- ✓ Patients below the age of 18 years.
- ✓ Teeth with pulpal involvement.
- ✓ Teeth with dental caries.

Data analysis

The data collected were reviewed and cross verified. The collected data is entered in MS Excel sheet, and transferred to SPSS version 21 for analysis. Independent variables were PID, Name; Dependent variables were age, gender, tooth number, apical preparation size. Chi square test was used to analyse the association. P value less than 0.05 was considered statistically significant. Results were presented in the form of bar diagrams.

RESULTS

The results of the study are presented as bar diagrams below. Figure 1 represents the frequency distribution of age group. Figure 2 represents the frequency distribution of teeth numbers. Figure 3 represents the frequency distribution of etiology of tooth discoloration.

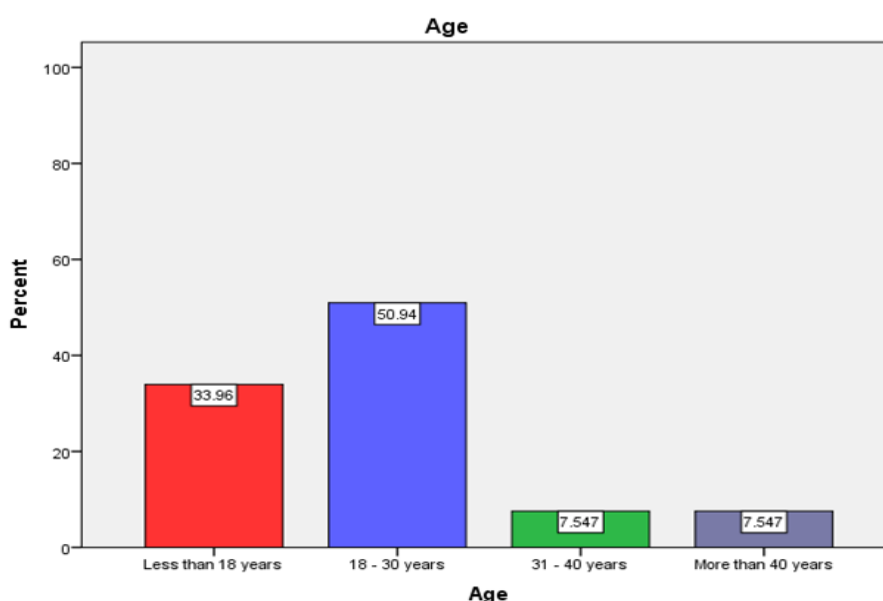


Figure 1: This bar chart represents the frequency distribution of age group. Majority of the patients were between the age group of 18-30 years (50.9%) followed by less than 18 years (33.9%), 31-40 years and more than 40 years (7.5%).

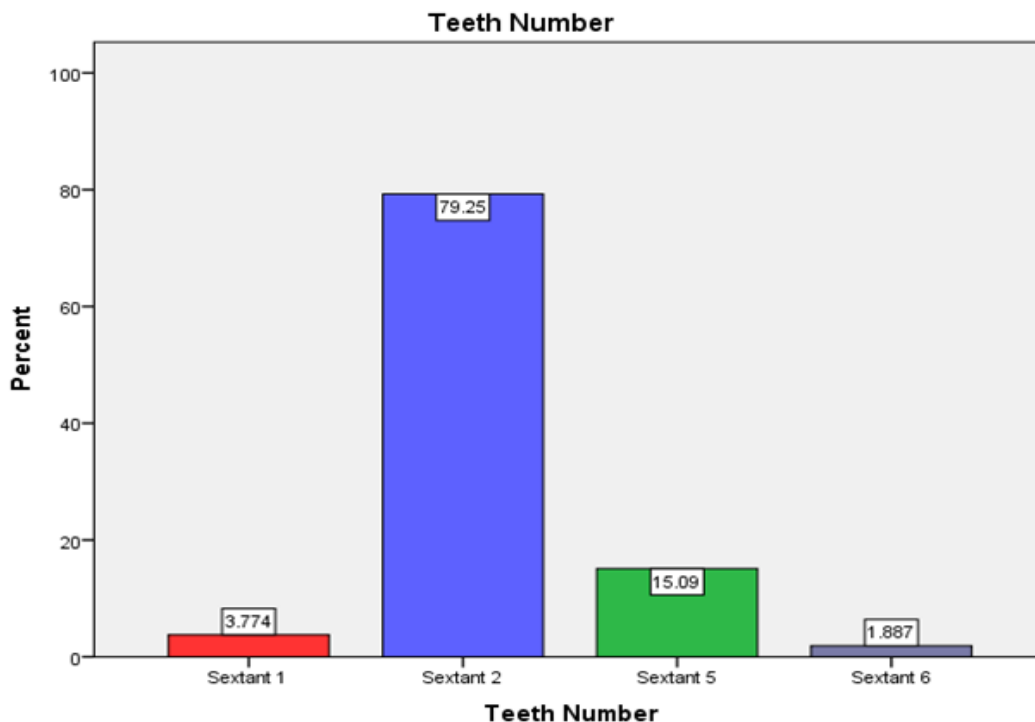


Figure 2: The bar chart represents the frequency distribution of teeth numbers. Majority of the participants have undergone treatment in sextant 2 (79.7%) followed by sextant 5 (15%), sextant 1 (3.7%) and sextant 6 (1.8%).

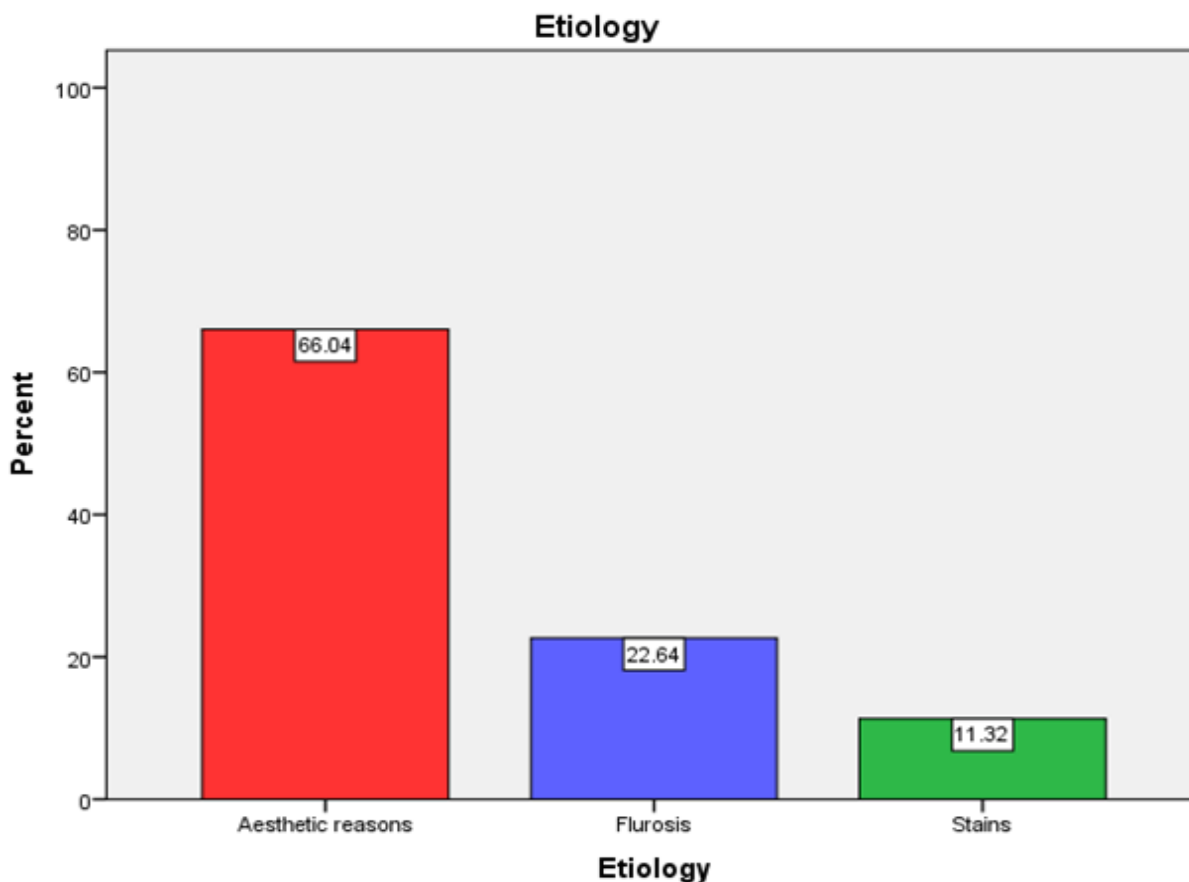


Figure 3: The bar chart represents the frequency distribution of etiology of tooth discoloration. Majority of the patients have undergone due to aesthetic reasons (66%) followed by fluorosis (22.6%) and stains (11.3%).

DISCUSSIONS

From our current study it is seen that around 50.9% of the participants were between the age group of 18-30 years which correlates with the study done by Felmen et al. [33].

As we age, the teeth naturally yellow over time. This is a result of both extrinsic and intrinsic discoloration. For starters, the dentin layer of the teeth becomes more yellow over the years. And the dental enamel also grows thinner with time, which makes the yellow dentin more visible. For younger adults this occurs most commonly due to the kind of food they consume and their everyday habits [33,34].

From the findings of the current study it is seen that, around 79.2% of the patients have undergone treatment for discoloration in relation to sextant 2 which is maxillary anterior which correlates with the study done by Tunca et al., [35,36].

Esthetics has become a major component of modern dentistry especially in the upper anterior of a patient. Good esthetics is achieved through art and symmetry of the teeth and face which enhances the appearance as well as the function of the teeth, oral cavity, and face. Also in case of upper anterior ceramic veneers displayed promising results when considering the esthetic and mechanic criteria's. The new smile of the patient was satisfactory with excellent esthetic appearance [37].

The findings from the current study shows that around 66% of the participants have undergone bleaching therapy due to aesthetic reasons followed by fluorosis (22.6%) and stains (11.3%). Association between age and etiology was done and P value was found to be 0.075 which is statistically not significant. Fluorosis is an endemic disease, prevailing in about 25 countries globally [38]. Dental fluorosis is an acquired defect of enamel due to the exposure of an individual to excessive fluoride levels during tooth development. It could result in mild-to-severe discoloration of teeth, which might necessitate esthetic correction. Bleaching is one of the common treatment modalities used in the esthetic correction of such cases. In-office power bleaching is one of the techniques of tooth bleaching that involves clinical application and activation of the bleaching agent with light to accelerate the bleaching process [39]. Discolored teeth are more of a cosmetic issue rather than a medical issue. Brownish-yellow or white patches are usually a sign of poor cleaning habits or staining caused by food, drinks, and other activities [40]. However, some stains can be indicative of unhealthy behavior that can lead to serious issues with the teeth.

CONCLUSION

Within the limits of the current study it is proven that, the majority of the patients have undergone treatment

for discoloration due to aesthetic reasons. Tooth Staining has several etiologic factors ranging from simple enamel hypoplasia to severe dental fluorosis. Many colour changes can be encountered when dealing with tooth discoloration. An understanding of the disease process is essential in determining the appropriate treatment modalities. Good preventive care can prolong the clinical health of dental tooth structures.

ACKNOWLEDGEMENT

The authors would thank all the participants for their valuable support and authors thank the dental institution for the support to conduct.

CONFLICT OF INTEREST

Nil.

SOURCE OF FUNDING

The present project is supported/funded/sponsored by

- ✓ Saveetha Institute of Medical and Technical Sciences, Saveetha Dental College and Hospitals, Saveetha University, Chennai, India.
- ✓ Al Fajr index.

REFERENCES

1. American Association for the Advancement of Science. Section on medical sciences. Subsection on dentistry. Fluorine and Dental Health. 1942.
2. Ahmad I. Anterior dental aesthetics: Dental perspective. Br Dent J 2005; 199:135-141.
3. Brandt R. Use of microabrasion to improve dental aesthetics. Br Dent J 2002; 193:151-151.
4. Ahmad I. Anterior dental aesthetics: Facial perspective. Br Dent J 2005; 199:15-21.
5. de Rezende VS, Fonseca-Silva T, Drumond CL, et al. Do patients with extrinsic black tooth stains have a lower dental caries experience? A systematic review and meta-analysis. Caries Res 2019; 53:617-627.
6. Chen L, Zhang Q, Wang Y, et al. Comparing dental plaque microbiome diversity of extrinsic black stain in the primary dentition using Illumina MiSeq sequencing technique. BMC Oral Health 2019; 19:269.
7. Wakiaga JM, Brunton P, Silikas N, et al. Direct versus indirect veneer restorations for intrinsic dental stains. Cochrane Database Syst Rev 2015; CD004347.
8. Sulieman M. An overview of tooth discoloration: extrinsic, intrinsic and internalized stains. Dent Update 2005; 32:463-471.
9. Cortés-Bretón Brinkmann J, Albanchez-González MI, Lobato Peña DM, et al. Improvement of aesthetics in a patient with tetracycline stains using the injectable composite resin technique: Case report with 24-month follow-up. Br Dent J 2020; 229:774-778.

10. Gan Z, Hu X, Xu X, et al. A portable test strip based on fluorescent europium-based metal-organic framework for rapid and visual detection of tetracycline in food samples. *Food Chem* 2021; 354:129501.
11. Kumar A, Kumar V, Singh J, et al. Drug-induced discoloration of teeth: An updated review. *Clin Pediatr* 2012; 51:181-185.
12. Watts AM, Addy M. Tooth discolouration and staining: A review of the literature. *Br Dent J* 2001; 190.
13. Muthukrishnan L. Imminent antimicrobial bioink deploying cellulose, alginate, EPS and synthetic polymers for 3D bioprinting of tissue constructs. *Carbohydr Polym* 2021; 260:117774.
14. PradeepKumar AR, Shemesh H, Nivedhitha MS, et al. Diagnosis of vertical root fractures by cone-beam computed tomography in root-filled teeth with confirmation by direct visualization: A systematic review and meta-analysis. *J Endod* 2021; 47:1198-1214.
15. Chakraborty T, Jamal RF, Battineni G, et al. A review of prolonged post-COVID-19 symptoms and their implications on dental management. *Int J Environ Res Public Health* 2021; 18.
16. Muthukrishnan L. Nanotechnology for cleaner leather production: A review. *Environ Chem Lett* 2021; 19:2527-2549.
17. Teja KV, Ramesh S. Is a filled lateral canal-A sign of superiority? *J Dent Sci* 2020; 15:562-563.
18. Narendran K, Jayalakshmi, Ms N, et al. Synthesis, characterization, free radical scavenging and cytotoxic activities of phenylvilangin, a substituted dimer of embelin. *Int J Pharm Sci* 2020; 82.
19. Reddy P, Krithikadatta J, Srinivasan V, et al. Dental caries profile and associated risk factors among adolescent school Children in an Urban South-Indian City. *Oral Health Prev Dent* 2020; 18:379-386.
20. Sawant K, Pawar AM, Banga KS, et al. Dentinal microcracks after root canal instrumentation using instruments manufactured with different NiTi alloys and the SAF system: A systematic review. *Adv Sci Inst Ser E Appl Sci* 2021; 11:4984.
21. Bhavikatti SK, Karobari MI, Zainuddin SLA, et al. Investigating the antioxidant and cytocompatibility of *Mimusops elengi linn* extract over human gingival fibroblast cells. *Int J Environ Res Public Health* 2021; 18.
22. Karobari MI, Basheer SN, Sayed FR, et al. An *In Vitro* stereomicroscopic evaluation of bioactivity between Neo MTA Plus, Pro Root MTA, biodentine & glass ionomer cement using dye penetration method. *Materials* 2021; 14.
23. Rohit Singh T, Ezhilarasan D. Ethanolic extract of *Lagerstroemia speciosa* (L.) Pers., induces apoptosis and cell cycle arrest in HepG2 cells. *Nutr Cancer* 2020; 72:146-156.
24. Ezhilarasan D. MicroRNA interplay between hepatic stellate cell quiescence and activation. *Eur J Pharmacol* 2020; 885:173507.
25. Romera A, Peredpaya S, Shparyk Y, et al. Bevacizumab biosimilar BEVZ92 versus reference bevacizumab in combination with FOLFOX or FOLFIRI as first-line treatment for metastatic colorectal cancer: A multicentre, open-label, randomised controlled trial. *Lancet Gastroenterol Hepatol* 2018; 3:845-855.
26. Raj RK. β -Sitosterol-assisted silver nanoparticles activates Nrf2 and triggers mitochondrial apoptosis via oxidative stress in human hepatocellular cancer cell line. *J Biomed Mater Res A* 2020; 108:1899-1908.
27. Vijayashree Priyadharsini J. In silico validation of the non-antibiotic drugs acetaminophen and ibuprofen as antibacterial agents against red complex pathogens. *J Periodontol* 2019; 90:1441-1448.
28. Priyadharsini JV, Vijayashree Priyadharsini J, Smiline Girija AS, et al. In silico analysis of virulence genes in an emerging dental pathogen *A. baumannii* and related species. *Arch Oral Biol* 2018; 94:93-98.
29. Uma Maheswari TN, Nivedhitha MS, Ramani P. Expression profile of salivary micro RNA-21 and 31 in oral potentially malignant disorders. *Braz Oral Res* 2020; 34:e002.
30. Gudipaneni RK, Alam MK, Patil SR, et al. Measurement of the maximum occlusal bite force and its relation to the caries spectrum of first permanent molars in early permanent dentition. *J Clin Pediatr Dent* 2020; 44:423-428.
31. Chaturvedula BB, Muthukrishnan A, Bhuvaraghan A, et al. Dens invaginatus: a review and orthodontic implications. *Br Dent J* 2021; 230:345-350.
32. Kanniah P, Radhamani J, Chelliah P, et al. Green synthesis of multifaceted silver nanoparticles using the flower extract of *Aerva lanata* and evaluation of its biological and environmental applications. *Chem Select* 2020; 5:2322-2331.
33. Felman D, Parashos P. Coronal tooth discoloration and white mineral trioxide aggregate. *J Endod* 2013; 39:484-487.
34. Teo CS. Management of tooth discolouration. *Ann Acad Med Singapore* 1989; 18:585-590.
35. Raja DR, Nesappan T. Aesthetic correction and replacement of missing tooth in maxillary aesthetic zone using modified FPD with loop connectors: A case report. *Int J Dent Sci Res* 2014; 2:73-75.
36. Tunca M, Kaya Y. Effect of various orthodontic adhesives on enamel colour changes after fixed treatment. *J Orofac Orthop* 2021.
37. Heinz U. Quark-gluon transport theory I. The classical theory. *Ann Phy* 1985; 161:48-80.
38. Gupta R, Psm SD, SMS Medical College, et al. Comparison of associating factors of dental fluorosis in urban and rural children in Jaipur, (Raj) India. *IOSR J Dent Med Sci* 2013; 10:38-42.
39. Raut AW, Mantri V, Gedam PV, et al. Conservative esthetic management of severe dental fluorosis with in-office power bleaching. *Ann Afr Med* 2020; 19:211-214.
40. Silva PAM, Fernández AR, Macías LAG. Neutrosophic statistics to analyze prevalence of dental fluorosis. *Infinite Study* 2020.