

Effect of 1% Hyaluronic Acid and 0.20% Chlorhexidine Combination on Post Extraction Soft Tissue Healing: A Randomized Controlled Study

Gharaa Amer Mohammed*, Sahar Shakir Al-Adili, Sahar Abdualkader Ismaeel

Department of Oral and Maxillofacial Surgery, College of Dentistry, University of Baghdad, Baghdad, Iraq

HOW TO CITE THIS ARTICLE:

Gharaa Amer Mohammed, Sahar Shakir Al-Adili, Sahar Abdualkader Ismaeel, Effect of 1% Hyaluronic Acid and 0.20% Chlorhexidine Combination on Post Extraction Soft Tissue Healing: A Randomized Controlled Study, J Res Med Dent Sci, 2023, 11 (01): 162-167.

CorrDtls

Corresponding author: Dr. Gharaa Amer Mohammed

E-mail: ghraa.hussein1909@codental.uobaghdad.edu.iq

Received: 25-Oct-2022, Manuscript No. JRMDS-22-62363;

Editor assigned: 28-Oct-2022, PreQC No. JRMDS-22-62363 (PQ);

Reviewed: 11-Nov-2022, QC No. JRMDS-22-62363;

Revised: 26-Dec-2022, Manuscript No. JRMDS-22-62363 (R);

Published: 11-Jan-2023

ARMAMENTARIUM (INSTRUMENTS AND MATERIALS)

Instruments for teeth extraction

Instruments for diagnosis: Probe, mirror, tweezers (Aesculap/Germany).

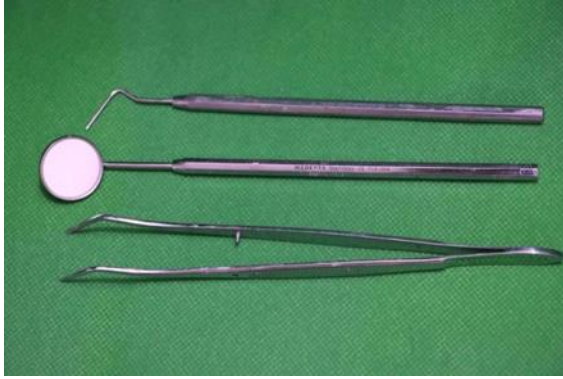

Figure1: Diagnostic Instruments.

Anesthetic Instruments

- Dental syringe (Aesculap/Germany).

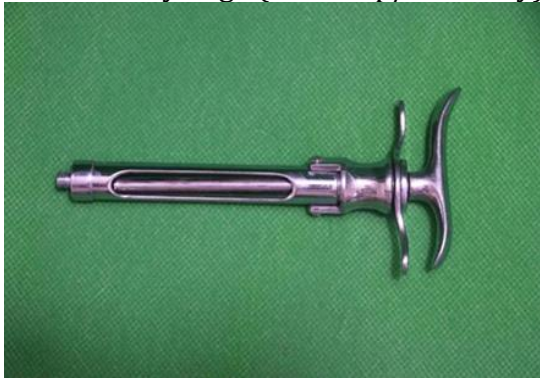

Figure 2: Dental syringe (Aesculap/Germany).

- **Dental needle:** C-K Ject disposable anesthetic needles 27G.

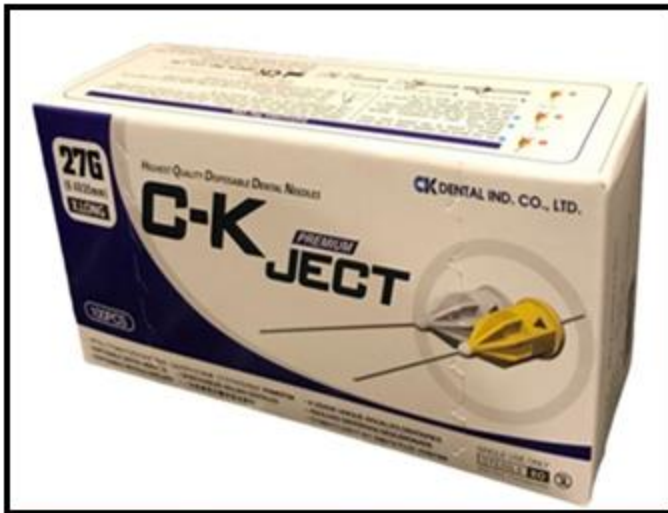

Figure 3: C-K Ject disposable anesthetic needles (CK digital IND. Co. Ltd./Korea) 27G.

Instruments for tooth extraction

- Premolar dental extraction upper forceps SSI786-105 (English pattern) (medical expo company).

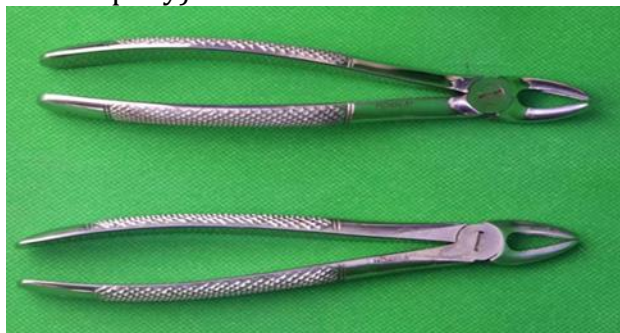

Figure 4: Premolar dental extraction upper forceps SSI786-105 (English pattern) (medical expo company).

- Premolar dental extraction lower forceps SSI786-105 (English pattern) (medical expo company).

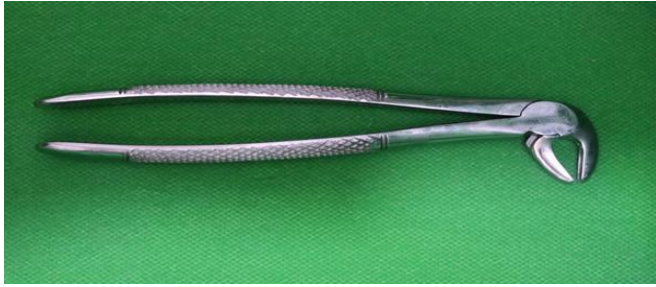

Figure 5: Premolar dental extraction lower forceps SSI786-105(English pattern) (medical expo company).

Instrument for dental socket measurement and gel application

- Periodontal probe (Aesculap/Germany).

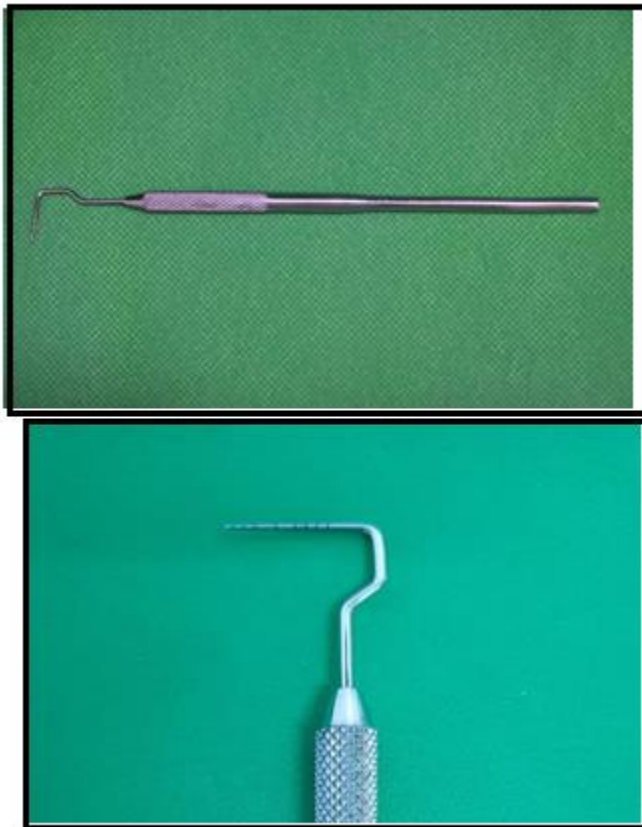


Figure 6: Periodontal probe (Aesculap/Germany).

- Disposable syringes (10 ml).

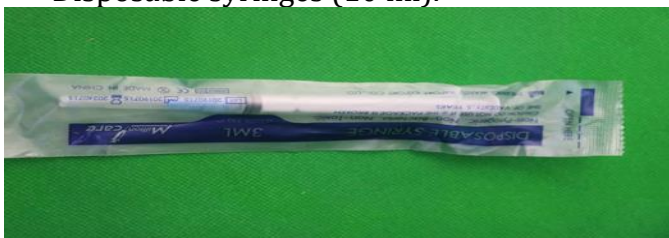

Figure 7: Disposable syringes (10 ml).

Other instrument

- Occlusal mirror.
- Check retractor.
- Tongue retractor.

Material

- Perio kin (0.20% chlorohexidie+HA1%) Kin company.

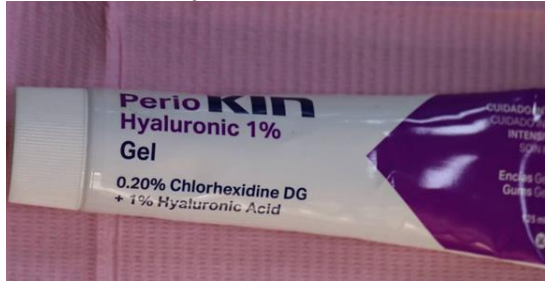

Figure 8: Perio kin (20% chlorohexidie+HA1%) Kin company/Espain.

- Cotton.



Figure 9: Cotton.

- Autoclave (Melag, Germany) and sterilization pouch (ADS, Australia).



Figure 10: A) Autoclave (Melag, Germany); B) Sterilization pouches (ADS, Australia).

Devises

- Canon camera 90D (Japan) (Figure 11).



Figure 11: Canon camera 90D.

- Intraoral scanner medit i700 with laptop (MEDIT/Korea) (Figure 12).

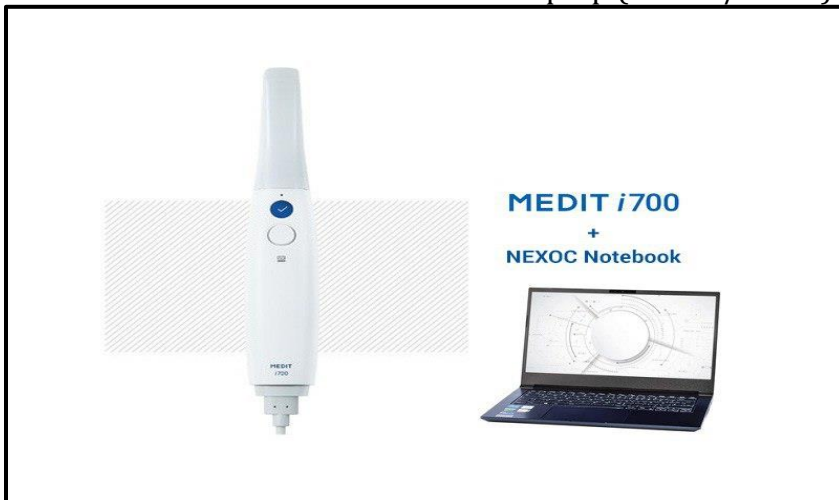

Figure 12: Intraoral scanner.

Software

- Medit compare 1.1.1.61.
- Exocad.
- SPSS.

Medications

Local Anesthesia (LA); lidocaine hydrochloride 2% with adrenaline 1: 80,000 (Figure 13).



Figure 13: 2.2 mL glass cartridge (Huons Co. Ltd. Korea).

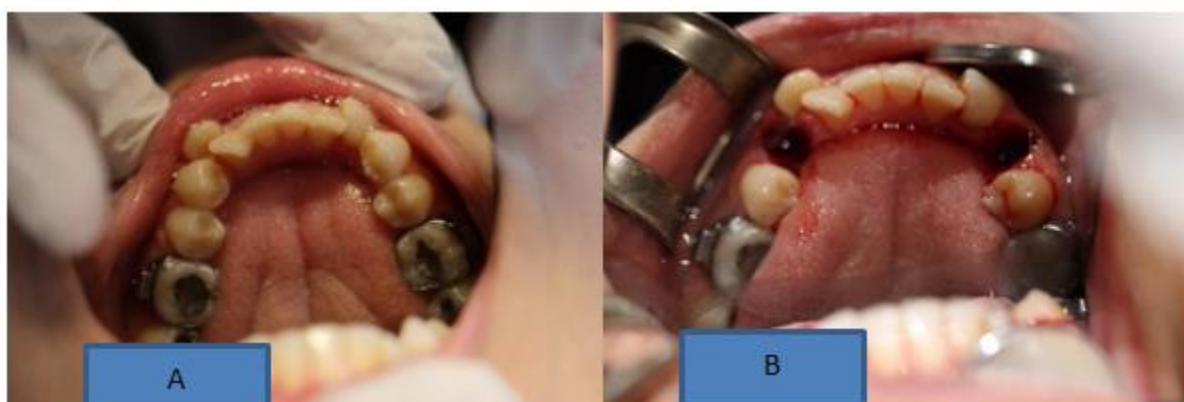

Figure 14: A traumatic extraction procedures.

Scanning by Inter oral scanner and measurement for buccopalatal or buccolingual and mesiodistal made by using medit compare 1.11.61 software to assess wound closure rate by a college operator out of the study.

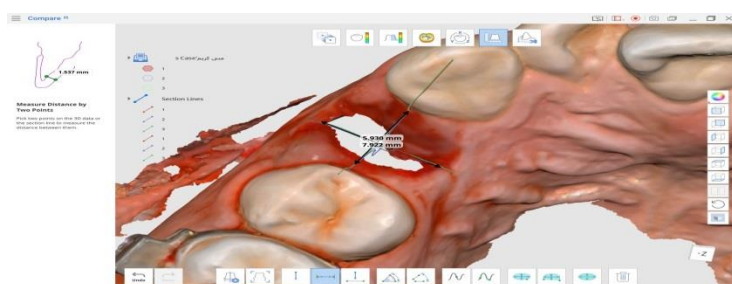


Figure 15: Tooth extracting scanning was made by inter oral scanner.

Assessment of Wound Healing Scale (WHS) according to criteria done by Vandana Shenoy, et al. with aiding of periodontal probe socket for socket depth measured immediately post extraction as shown in figure 16.

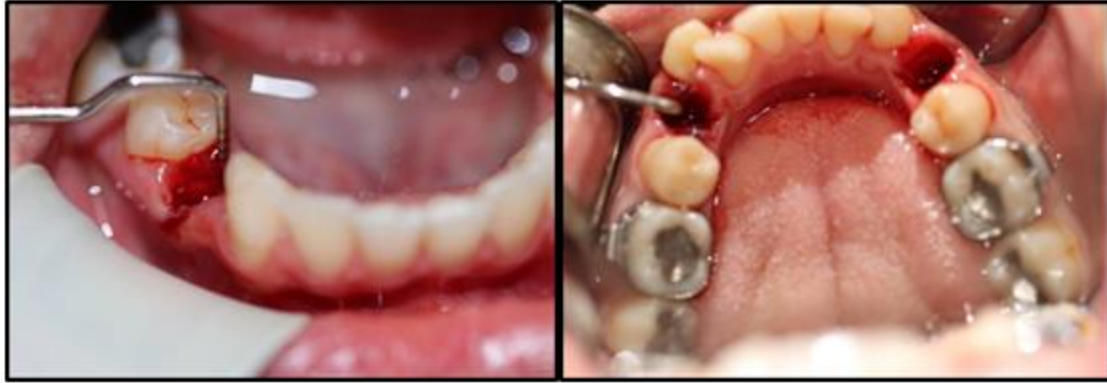

Figure 16: Wound Healing Scale (WHS) according to criteria done by (Vandana Shenoy, et al.) with aiding of periodontal probe after immediately post extraction.

Then other operator (a colleague outside of the research study) filled the selected socket (in the study group according to the randomization) with bioadhesive Perio kin (0.5 ml of 20% chlorohexidine+HA1%) manufactured by Kin company and provided by kin company delegate/Baghdad/Iraq). Application of the HA gel was made by using a sterile disposable syringe and needle (10 ml), while the contralateral socket was left untreated, naturally filled with blood clot (Figure 17).

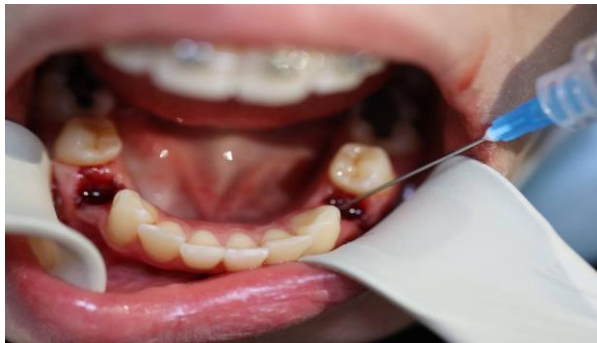

Figure 17: Application of the HA gel was made by using a sterile disposable syringe and needle (10 ml).

Scanning and wound healing assessment with aid of periodontal probe was repeated 3 and 7 days post extraction as shown in figure 18.

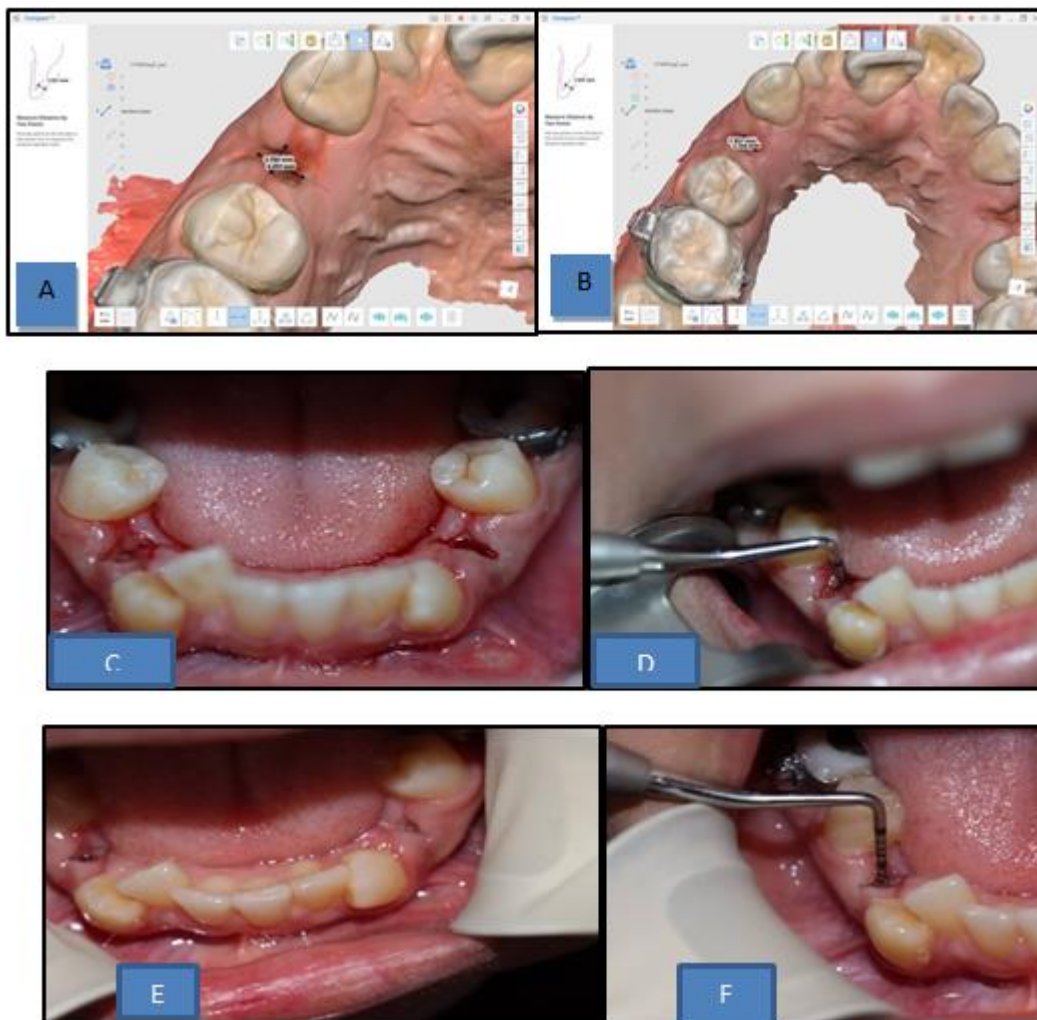


Figure 18: A and B: Wound closure rate 3 and 7 days respectively; C and D: Wound Healing Scale (WHS) with aiding of periodontal probe after 3 days, E and F WHS after 7 days according to criteria done by (Vandana Shenoy, et al.).